

## DIFFICULT TO DIAGNOSE INTRAABDOMINAL TUMOR – PSEUDOMYXOMA PERITONEI

**Ignatov V., K. Ivanov, N. Kolev, D. Hristov, A. Tonev, T. Temelkov**

*Department of General and operative Surgery, University Hospital “St. Marina”*

**Reviewed by: Assoc. Prof. R. Madjov, MD, PhD**

### ABSTRACT

**Pseudomyxoma peritonei (PMP) is a rare neoplastic, chronic and insufficient disease, which has the the characteristics of the disseminated mucinous ascites and the presence of peritoneal implants. The making of precise and well-timed diagnosis is a difficult process because of the lack specific symptoms. The exact preoperative diagnosis ‘PMP’ can be prescribe after CT-imaging, which is sensitive with its ‘mussel shell’ symptom on the surface of the visceral organ, resulting from the compression of the viscous mucinous ascites and the presence of fibrosis. We report a rare case of our practice, with anamnesis of abdominal swelling, lost of appetite, consumptive syndrome – more than 10 kilos for two months. The difficulties in diagnostic process were overwhelmed. Despite of the quantity of the studies, directed to the treatment of PMP, this disease stay constantly enigmatic with prolonged clinical elapsing and the high level of recurrency in the complex treatment and have to be discussed the application of operative methods and chemotherapy**

Pseudomyxoma peritonei (PMP) is a rare neoplastic, chronic and insufficient disease, which has the the characteristics of the disseminated mucinous ascites and the presence of peritoneal implants. (1)

There are two different biological types, which have prolonged elapse and tendency to be aggressive:

- Disseminated peritoneal adenomatosis (DPA)- benign type
  - Peritoneal mucinous carcinosis (PMC)- malignant type
- PMP is female-like tumor and is associated with the presence of ovarian mucinous tumor. It is very rare met in men, because of the other type of origin – lesions of the appendix!!!! Other possible primary tumor sources could be lesion in the rectum, colon, gall-bladder, pancreas, urachus, bladder, mammal gland, and lung, but they are very rare and are associated with peritoneal mucinous carcinosis (PMC) (2)

According Solkar et al. 2004, only 10% of the patients with PMP have 5.5 year survival rate after the diagnosing. (3, 4)

The making of precise and well-timed diagnosis is a difficult process because of the lack specific symptoms. The exact preoperative diagnosis ‘PMP’ can be prescribe after CT-imaging, which is sensitive with its ‘mussel shell’ symptom on the surface of the visceral organ, resulting from the compression of the viscous mucinous ascites and the presence of fibrosis. Due to this image method there often can be found multiple cystic masses with lipid consistency in the peritoneum. They could have ferrules of calcificates with typical festooning of the liver outlines, the thickness of the omentum, and the differences in the compression of visceral organs and structures. The preoperative ultrasound examination frequent shows raw, sluggish ascites with septal adhesions and high levels of ultrasound consistency. The combination of clinical results and radiological signs are highly specifying for the diagnosis of PMP. In patients with occasional find, radiology can find abdominal

calcification plates, ascites and unseparated soft tissue masses. In this cases the method of choice is CT. (5)

The accuracy and specificity of MRI in the diagnostics is not clear yet.

The explorative diagnostic laparoscopy is indicated as gold standard in diagnosis-making and consequent morphological investigation.

A study of O’Connell J.T. et al. 2002 preceints PMP as neoplastic disease from MUC-2 producing goblet cells. The extracellular accumulation of mucin is due to alteration of glucoprotein in the cells extremas in the tumor’s stroma. (6) The most frequent operations are according to surgical treatment of PMP:

- Right Hemicolectomy- 88%
- Resection of the sigma- 65%
- Gastrectomy- 47%
- Colectomy- 6%
- Splenectomy- 79%
- Cholecystectomy- 76%
- Hysterectomy and bilateral salpingo-ooforectomy 50%
- Omentectomy- 60%

(De Simone M, et al. 2006) (7)

The developing of treatment strategy in cases of PMP is a discutable question, yet. Complex therapy is applied, including citoreductive surgical procedure and segmentary resection the obturated organ and omentectomy. Reoperation is necessary in the cases of recidives.

In a study of Sugarbaker et al. 1995, they proved that intraoperative chemotherapy with 5-fluorouracil and Mythomicyn C have minimal effect in the reduction of “tumor implants” of atypical epithelium and don’t provoke apoptosis of these cells. (8)

Deraco et al. 2006 make resection of mainly engaged organ and intraoperituneal citoreductive chemotherapy with

Mythomicyn C, warmed up to 42 °C. (9) The aim is to be removed the tumor “in toto” and to be destroyed the residual small tumor nodes, according to Smeenk et al. 2006. They notice that the conducting of combined therapy, despite of high levels of toxicity, enlarge the survival rate. (10)

Miner J.T. et al. 2005 defined that the prognosis of the outcome is connected with :

- Tumor differentiation (G) – morphologically confirmed.
- Preoperative extend of the tumor
- The resection of the targeted organ and citoreductive therapy. (11)

The most informative carcino markers are CEA and CA-19-9, which are increasing their levels in case of recidive. (12)

According to Sugarbaker et al. 1995, it is necessary to be applied chemotherapy with 5fluorouracil + Mythomicyn C with ‘Second look’ when are made big operations with grate extend of the surgery. The tumor markers have to be investigated in a 3 month period CT have to be made in a 6 month period. (8)

Deraco et al. 2003 classify the disease in four grade scale, according to followed criteria for mortality and morbidity:

- I. Grade – without complications
- II. Grade – small and light complications
- III. Grade – serious complications (demanding reoperation and intensive care)
- IV. Grade – in status that led to exitus letalis (13)

## RESULTS

We present a case of PMP, a male on 53 years, who enter in the Clinic of General and Operative Surgery with anamnesis of abdominal swelling, lost of appetite, consumptive syndrome – more than 10 kilos for two months and laboratory data as presented:

Hct	0,35
Leu	6,3
CYE	94
CEA	17,3
CA19-9	1257
Protein	75
Albumin	36
Urea	3,8
Glucose	4,3

By the applied abdominal ultrasonography we found a presence of moderate qantity of ascites, which fluctuated with ultrasonogenic structures and fixated intestinal stitches to the liver and diaphragma. We evacuate yellow ascites, which gelatinize as soon as it was get out of the body. The CT data showed us plenty of cystic lesions in the perito-

neum, which were compressed the liver. The liver had a typical festoon image. The consistency of the ascites was about 20 HE. We found hevily thicked omentum majos and clinical view as PMP Through the exploration of the abdominal cavity in planned order, we found plenty brids between abdominal organs, yellow-like jelly ascites around 2 l (includes many light formation)

We found intact appendix, which was situated medial and retrperitoneal. The omentum was enveloped by the tumor formation with extends of 15/10/5 cm. (Fig. 1 - 7)

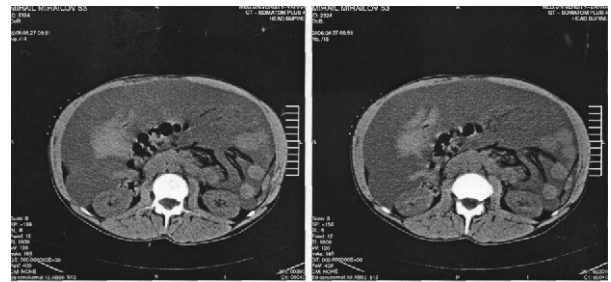


Fig. 1.

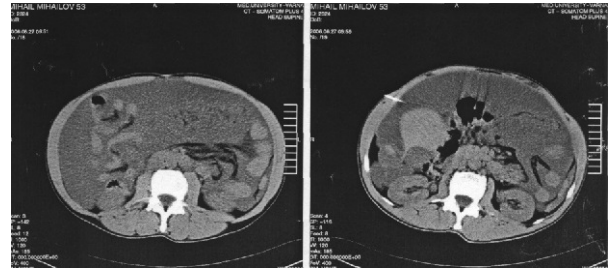


Fig. 2.

Omentectomy and lavage was made by serum physiologicum. At last, we put two drainages.

The early postoperative period was smooth, under the protection analgetics, cristaloid solutions, monosaccharids solutions and low-weight heparins.

Morphologically investigated materials were introduced by multiple necrosis and confluated mucous tracts, separated by different in size septal brids with hyperfollicular vessels and lymphotic infiltrats. Morphological diagnosis: Pseudomyxoma peritonei.

The patient was directed for initiating of systematic chemotherapy with Mythomicyn C and 5-fluorouracil.

## CONCLUSION

Despite of the quantity of the studies, directed to the treatment of PMP, this disease stay constantly enigmatic with prolonged clinical elapsing and the high level of recurrency in the complex treatment and have to be discussed the application of operative methods and chemotherapy.

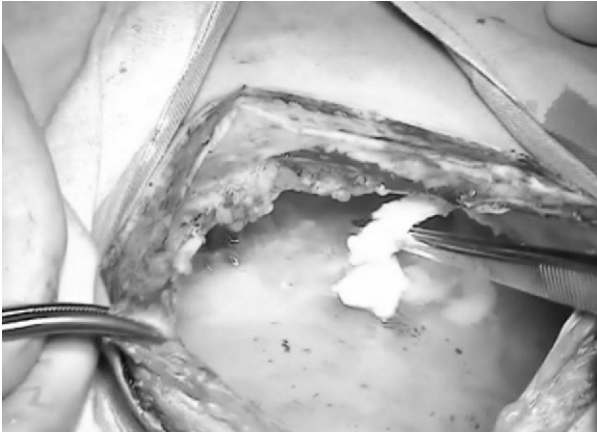

Fig. 3.

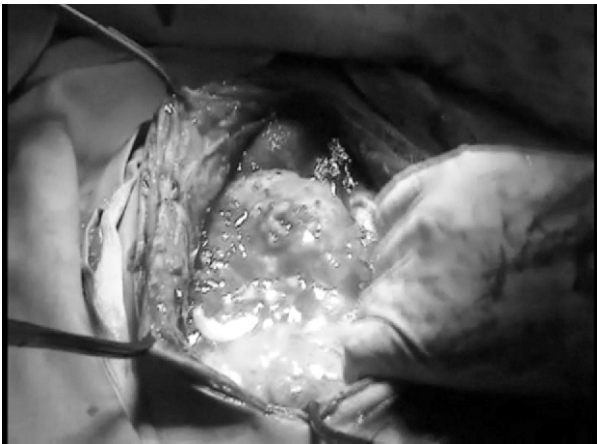


Fig. 4.



Fig. 5.

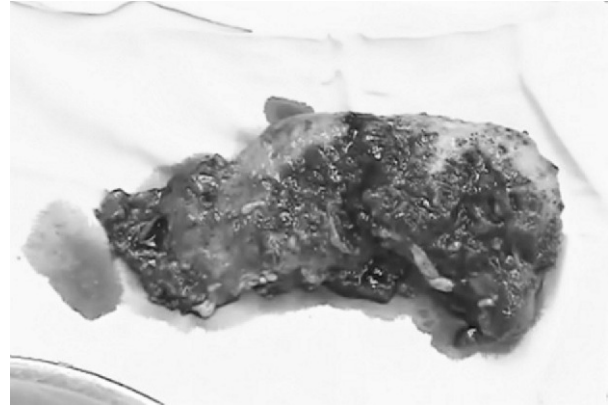


Fig. 6.

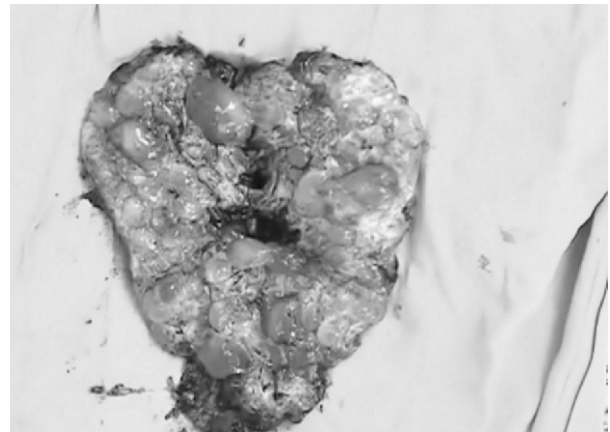


Fig. 7.

## REFERENCES

1. Fann JJ, Vierra M, Fisher D, Oberhelman HA Jr, Cobb L. Pseudomyxoma peritonei. *Surg Gynecol Obstet.* 1993 Nov; **177**(5):441-7.
2. Galani E, Marx GM, Steer CB, Culora G, Harper PG. Pseudomyxoma peritonei: the 'controversial' disease. *Int J Gynecol Cancer.* 2003 Jul-Aug; **13**(4):413-8.
3. Solkar MH, Akhtar NM, Khan Z, Parker MC. Pseudomyxoma extraperitonei occurring 35 years after appendectomy: a case report and review of literature *World J Surg Oncol.* 2004 Jun **4**;2(1):19.
4. Solkar MH, Khan MZ, Parker MC. Pseudomyxoma peritonei confined to the retroperitoneum occurring 35 years after appendectomy. *Int J Colorectal Dis.* 2004 Jul; **19**(4): 399-400. Epub 2004 Apr 9.
5. Hossain J, Malabarey T, al-Mofleh I, Hawass NE, Ismail AH. Clinical and radiological features of pseudomyxoma peritonei. *JR Soc Med.* 1989 Oct; **82**(10):600-2.
6. O'Connell JT, Hacker CM, Barsky SH. Pseudomyxoma peritonei is a disease of MUC2-expressing goblet cells. *Am J Pathol.* 2002 Aug; **161**(2): 551-64.
7. De Simone M, Vaira M, Caponi A, Ciaccio B, Fiorentini G, Turrisi G, Ferri L, Buti G. Ten years experience in the treatment of pseudomyxoma peritonei by cytoreduction, peritonectomy and semi-closed hyperthermic antineoplastic peritoneal perfusion. *In Vivo.* 2006 Nov-Dec; **20**(6A):725-7.
8. Sugarbaker PH. Pseudomyxoma peritonei. A cancer whose biology is characterized by a redistribution phenomenon *Ann Surg.* 1994 Feb; **219**(2):109-11.
9. Deraco M, Kusamura S, Laterza B, Favaro M, Fumagalli L, Costanzo P, Baratti D.

- Cytoreductive surgery and hyperthermic intra-peritoneal chemotherapy (HIPEC) in the treatment of pseudomyxoma peritonei: ten years experience in a single center. *In Vivo*. 2006 Nov-Dec; **20**(6A): 773-6.
10. Smeenk RM, Verwaal VJ, Zoetmulder FA. Pseudomyxoma peritonei. *Cancer Treat Rev*. 2006 Dec **18**; In print
  11. Miner TJ, Shia J, Jaques DP, Klimstra DS, Brennan MF, Coit DG. Long-term survival following treatment of pseudomyxoma peritonei: an analysis of surgical therapy. *Ann Surg*. 2005 Feb; **241**(2):300-8.
  12. Carmignani CP, Hampton R, Sugarbaker CE, Chang D, Sugarbaker PH. Utility of CEA and CA 19-9 tumor markers in diagnosis and prognostic assessment of mucinous epithelial cancers of the appendix *J Surg Oncol*. 2004 Sep **15**;87(4):162-6.
  13. Deraco M, Gronchi A, Mazzaferro V, Inglese MG, Pennacchioli E, Kusamura S, Rizzi M, Anselmi RA Jr, Vaglini M. Feasibility of peritonectomy associated with intraperitoneal hyperthermic perfusion in patients with Pseudomyxoma peritonei Tumori. 2002 Sep-Oct; **88**(5):370-5.