

## THE ROLE OF VASCULAR ENDOTHELIAL GROWTH FACTOR AND ANTITHROMBIN III IN THE PATHOGENESIS OF THE OVARIAN HYPERSTIMULATION SYNDROME

E. Kovachev, I. Kozovski, V. Markova, K. Aleksandrov, S. Cherneva, S. Cvetkova

*Department of Obstetrics and Gynaecology, Centre of Assisted Reproductive Technology,  
Prof. Paraskev Stoyanov Medical University of Varna*

### ABSTRACT

Ovarian hyperstimulation syndrome (OHSS) is an iatrogenic complication of controlled ovarian hyperstimulation (COH). Its pathogenesis is not clarified yet. In the recent years a number of studies focused on the vascular endothelial growth factor (VEGF) and antithrombin III (AT III) indicators. VEGF is homodimeric, heparin-binding glycoprotein, stimulating vascular permeability. Antithrombin III is protease inhibitor of activated clotting factors. This study aimed at examining the VEGF-A<sub>165</sub> and AT III indicators with two OHSS patients. Two methods were used for the determination of the indicators of VEGF-A<sub>165</sub> and AT III: ELISA for VEGF and chromogenic assay for AT III. Kits of R/D Systems and American Diagnostica Inc. were used to estimate VEGF and AT III indicators in serum and plasma. There were higher indicators of VEGFA<sub>165</sub> (180pg/ml) and reduction of AT III indicators (48%) in the patient with a severe form of OHSS than in the control group while these indicators were normal in the patient with a moderate form of OHSS. Our results confirmed some published data concerning the importance of VEGF and AT III in the genesis of OHSS. This study should include a larger group of patients in order to follow-up statistically and authentically the variations of the indicators of both factors and their importance for OHSS.

**Key words:** OHSS, ART, VEGF, AT III, laboratory parameters, pathogenesis

The ovarian hyperstimulation syndrome (OHSS) is a serious and potentially life-threatening physiologic complication classically encountered in patients who undergo controlled ovarian hyperstimulation cycles (COH). It presents with a mild, moderate and severe form, according to Golan's classification. The following factors are of pathophysiological importance: polycystic ovarian syndrome (PCOS) (4); high estradiol levels; elevation of human chorion gonadotropin (HCG); activation of the prorenin-renin-angiotensin chain (3); increased synthesis of prostaglandins (PG), histamine, serotonin, and cytokines such as IL; deficiency of the enzyme 17-20 desmolase; role of inhibins and activins in ovarian physiology and pathology as well as role of the vascular endothelial growth factor (VEGF) and antithrombin III (AT III) (1,2). The increased capillary permeability and angiogenesis are significant factors in OHSS pathogenesis (8) (Fig. 1).

VEGF is a homodimeric, heparin-binding glycoprotein playing the key role of mediator in angiogenesis and stimulating vascular permeability. There are two tyrosine kinase receptors for VEGF (9) which are produced in theca interna and human granulosa cells where two fractions -

VEGFA<sub>165</sub> and VEGFA<sub>121</sub> predominate (5). AT III is a protease inhibitor of clot-activating factors and its deficiency may cause thrombosis. One possible way of decreasing AT III in patients with severe OHSS is a shift of albumin in extravascular space that may be accompanied by that of AT III because of its similar molecular weight.

Thromboembolic incidents can occur in association with OHSS and can be observed in patients with hereditary AT III deficiency with plasma active levels of 30-60% of AT III. Acquired AT III deficiency can be suspected with liver disease, DIC, nephrotic syndrome, pulmonary embolism, stroke and thrombophlebitis. In addition, oral contraceptive use may reduce AT III levels (6,10).

The objective of the present study was to investigate the levels of VEGFA<sub>165</sub> and AT III with two patients with OHSS and to establish their role in OHSS pathogenesis.

### MATERIAL AND METHODS

During the period from January, 2003 to January, 2004 in IVF Centre of Varna, two patients with moderate and severe form of the OHSS were examined. IVF-procedure was performed with inhibition of pituitary gland with GnRH-agonist, COH-long protocol - 'step up' depending on estradiol levels and follicular development. Exogenous gonadotropins were applied in a dose of 5000E or 10000E

#### Address for correspondence:

E. Kovachev, Dept. of Obstetrics and Gynaecology,  
Prof. Paraskev Stoyanov Medical University of Varna,  
BG-9002 Varna, 55 Marin Drinov St., Bulgaria

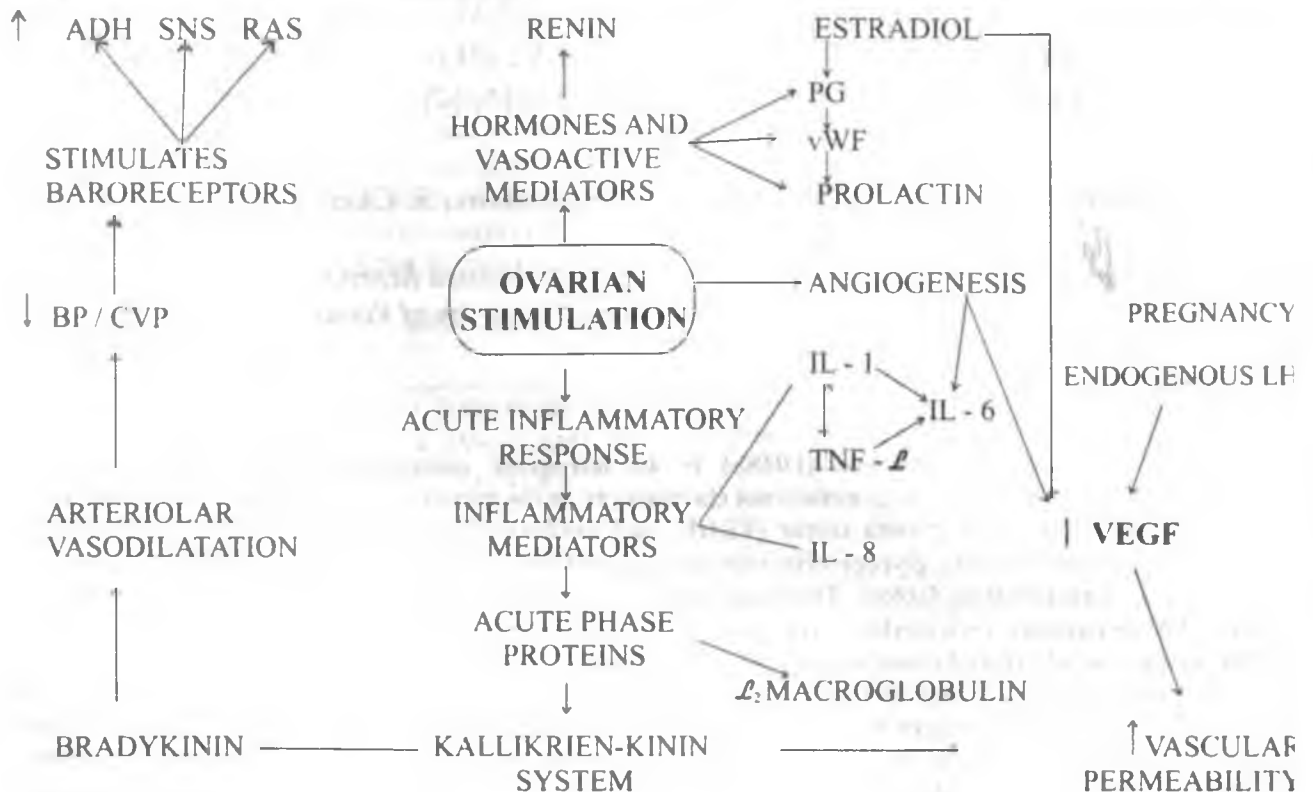


Fig. 1. Pathogenesis of OHSS

HCG (Pregnyl) and aspiration oocytes was done after 34-36h. On the third day after the puncture, three embryos were transferred. For luteal support, Utrogestan was applied. At the start of the stimulation as well as before application of HCG, estradiol (E<sub>2</sub>) and the standard blood parameters were measured. For establishing the levels of VEGF A<sub>165</sub> in serum, ELISA was used and kits of R/D-Systems centrifuged at 2000x.g. and stored at -20°C were made use of. Plasma AT III levels were measured through chromogenic assay kit of spectrophotometer - 405nm, centrifuged and stored at -20°C, 30min before use. Thrombin reagent, spectrozyme and dilution buffer of American Diagnostica Inc. were applied. For establishing the control levels of VEGFA<sub>165</sub> and calibration of AT III standards, a control group of 10 patients was formed who participated in IVF-programme - COH with no indication of OHSS, liver and hematologic diseases. VEGFA<sub>165</sub> and AT III were measured in serum and plasma. Blood samples for VEGFA<sub>165</sub> and AT III were taken on the second day after HCG-application. Referent range for VEGF does not exist, therefore, the recommendation of R/D-Systems is to establish control levels in the group of minimum 10 patients.

## RESULTS AND DISCUSSION

With the patient with 'late' OHSS (severe) form, the diagnosis was made on the 13<sup>th</sup> day after the injection of Pregnyl

5000E and the level of E<sub>2</sub> before application was 2,800pg/ml, 10 dominant follicles in the 2 ovaries were present. After 36h a puncture and aspiration of 11 oocytes of good quality was realized. ICSI-method was done because the reason was azoospermia of the husband. On the 3<sup>rd</sup> day after the puncture, embryo transfer of 3 embryos took place. The patient was admitted on the 13<sup>th</sup> day in our hospital in Varna with some complaints such as malaise, vomiting, abdominal discomfort, and respiratory distress. It was established that ovaries were 4/11cm with theca-lutein cysts, large amounts of ascites were revealed with ultrasound examination. OHSS was classified as a severe form of IV grade in reference to clinical and paraclinical parameters. The pregnancy test was positive, later on the ultrasound examination showed multiple pregnancy (bigemini) which, additionally, exacerbated OHSS. The paracentesis was realized with a view to the increased quantity of ascites and all therapeutic procedures for treatment of OHSS. Two live twins on the term were born with Caesarean section in 38g. w. and their weights were 2,600g and 2,750g, respectively. With the second patient with OHSS the diagnosis was established on the 10<sup>th</sup> day after stimulation with gonadotrophins. Preventive and therapeutic activities were done - 'step down' protocol, coasting HCG, early unilateral follicular aspiration, HCG of 5000E, puncture and aspiration of 14 oocytes, infusion of human albumin and antibiotic treatment. On the 3<sup>rd</sup> day, embryo transfer of 2 embryos

was conducted. The pregnancy was not proved, unfortunately. VEGFA<sub>165</sub> levels of control group were between 30-105pg/ml. (67,5pg/ml). The normal laboratory levels of

were normal, VEGFA<sub>165</sub> - 70 pg/ml and AT III - 95%, respectively. Table 1 shows the laboratory examinations of the patient with 'late' OHSS (severe) form.

Table 1. Laboratory indices of the patient with severe form of OHSS

Laboratory parameters	normal range	Number of days after the diagnosis of OHSS				
		1	3	6	8	11
hemoglobin	120-160 g/l	175	168	155	130	140
hematocrit	0.36-0.48	0.58	0.52	0.40	0.42	0.42
red blood cells	3.7 - 5.3*10 <sup>12</sup> /l	6.2	5.7	5.0	4.4	4.6
leukocytes	3.5- 10.5*10 <sup>9</sup> /l	17.0	14.0	10.2	8.9	7.0
platelets	130 -360*10 <sup>9</sup> /l	380.0	358.0	305.0	309.0	260.0
ESR	up to 20mm/h	22mm/h	-	17mm/h	-	6mm/h
time of bleeding	2 - 5 min	4.7	-	3.0	-	-
fibrinogen	2 - 4.5g/l	4.9	4.2	3.9	3.0	4.0
fibrinogen degradation products	< 10µg/ml	6.8	13.2	13.8	10.6	8.2
prothrombin time	11.5-15sec	14.5	13.8	15.2	13.2	12.8
activated partial thromboplastin time	28.0-38.0sec	36.0	-	31.0	-	-
total protein	60-83g/l	40.1	44.5	58.2	63.3	64.0
ASAT	2-18U/l	20.2	-	14.0	-	6.4
ALAT	2-18U/l	17.2	-	15.8	-	15.2
urea	2.6-7.2mmol	8.8	8.0	7.3	6.3	-
creatinine	58-9.6µmol/l	140	128	109	95	87
K <sup>+</sup>	3.5-5.6 mmol/l	5.5	5.1	3.9	4.0	3.6
Na <sup>+</sup>	136-151 mmol/l	148	-	140	-	-
pH	7.36-7.44	7.42	-	7.40	-	-
pO <sub>2</sub>	10.66-13.33kPa	11.2	10.72	-	11.6	12.0
pCO <sub>2</sub>	4.66-5.99kPa	6.1	5.82	-	4.92	5.2
urine	investigation for protein, sugar, ketons, bilirubin, urobilinogen					
24h	diuresis					
E <sup>2</sup> before application of HCG - 2,800ng/ml						
AT III-second day after HCG application - 48%	75-125%					
VEGFA <sub>165</sub> - second day after HCG application - 180ng/ml	Control group 30-105ng/ml					

AT III in plasma were 75-125% and of the control group - 80-109%. There was an increase of VEGFA<sub>165</sub> (180 pg/ml) and a decrease of AT III (48%) in the patient with 'late' OHSS. These parameters of the other case with OHSS

Pathogenesis of OHSS is still unknown but the increased capillary permeability and angiogenesis are primary components in it. Some authors report of OHSS complicated with thrombosis without hemoconcentration in a patient

with AT III deficiency, as well as of thromboembolic complications after hyperstimulation with hereditary AT III deficiency (10). The decrease of AT III may be a result of insufficient synthesis, high consumption, abnormal loss due to accompanying albumin in extravascular space (6). VEGF is the basic inductor of capillary permeability in OHSS and the main cause of ascites, pleural and pericardial effusion.

It is suspected that HCG application in the stimulation protocol causes VEGF synthesis (1). Other researchers consider VEGF a minor clinical marker of OHSS. It is reported that VEGF participates in premature rupture of the membranes. They emphasize its role in the genesis of placental hypoxia and its excretion as a potential early indicator of severe birth asphyxia. OHSS is classified as 'early' that develops within 3-7 days after ovulatory dose of HCG and 'late', after 12-17 days in women with multiple pregnancy. The parameters used during the stimulation for prediction of OHSS do not show any risk of development of 'late' OHSS.

There are different opinions about the rate of E<sub>2</sub> for prediction of OHSS. Some reports show a risk of 38% for severe OHSS with peak of E<sub>2</sub> reaching 6000pg/ml on the day of HCG application (9). Their reports which use the same criteria predict only a risk of 8,8% for development of severe OHSS (7). Some investigators claim that 'late' OHSS does not correlate with the peak rate of E<sub>2</sub> like in our case.

## CONCLUSION

The measurement of VEGF rate between the days of HCG application and embryo transfer is a possible marker concerning the risk for 'late' OHSS. Our results support in part the data published in the literature available about the importance of VEGF and AT III for OHSS pathogenesis. In our opinion, the study should include a larger group of patients to measure statistically the real fluctuation of the rates of both factors and their importance for OHSS.

## REFERENCES

1. Ковачев, Е., И. Козовски, В. Маркова, С. Чернева, и др. Някои аспекти на ОХСС.- В: IV. Национален конгрес по стерилитет, контрацепция и хормонозаместителна терапия. Боровец, 2003 г.- *Репрод. здраве*, 2003, № 2.
2. Ковачев, Е., И. Козовски, В. Маркова, С. Чернева, и др. Диагноза, клинична картина и проследяване на жени с ОХСС след ИВФ-ЕТ.- В: Юбилейна научна конференция. Стара Загора, 2002г.
3. Козовски, И., В. Маркова, М. Андонов. ОХСС при бременност след ИВФ-ЕТ.- В: Национална акушерска конференция. Китен, 1997г.
4. Козовски, И., В. Маркова, П. Шопова. ОХСС не е усложнение само на методите за асистирана репродукция.- В: VII. Национален конгрес по акушерство и гинекология. Варна, 1998г.
5. Geva, E., J. B. Jaffe. Role of VEGF in ovarian physiology and pathology.- *Fertil. Steril.*, **74**, 2000, No 3, 429-438.
6. Neulen, J., D. Wenzel, C. Hornig, E. Wunsch, et al. Poor responder - high responder: the importance of soluble VEGF-receptor 1 in ovarian stimulation protocols.- *Hum. Reprod.*, **16**, 2001, p. 84.
7. Levin, E. R., G. F. Rosen, D. Cassidenti, B. Yee, et al. Role of VEGF in ovarian hyperstimulation syndrome.- *J. Clin. Invest.*, **102**, 1998, 1978-1985.
8. Lee, A., L. Christenson, L. Stouffer, A. Burry, et al. VEGF levels in serum and follicular fluid of patients undergoing in vitro fertilization.- *Fertil. Steril.*, **68**, 1997, 305-311.
9. Ryo, E., D. Hagino, N. Yano, M. Sento, et al. A case of ovarian hyperstimulation syndrome in which antithrombin III deficiency occurred because of its loss into ascites.- *Fertil. Steril.*, **71**, 1999, 5.
10. Kligman, I., N. Noyes, C. A. Benadiva, Z. Rosenwaks, et al. Massive deep vein thrombosis in a patient with antithrombin III deficiency undergoing ovarian stimulation for in vitro fertilization.- *Fertil. Steril.*, **63**, 1995, 673-676.