

## MICROCIRCULATORY CHANGES IN PATIENTS WITH CHRONIC IRON-DEFICIENCY ANEMIA

Zh. Georgieva

Department of Propedeutics of Internal Medicine, Medical University of Varna, Varna

*Chronic anaemic hypoxia in iron-deficiency anaemia (IDA) determines substantial alterations in the microcirculatory bed: extravascular, vascular, and intravascular disorders as well as changes of diameter and linear density of the venular part of microcirculation. The author studied the correlation between the severity of microcirculatory changes and the degree of IDA as well as their reversibility after treatment. The microcirculatory bed of 255 female patients divided into groups with slight, moderate, and severe degree of IDA was estimated by the method of conjunctival biomicroscopy. Values of blood viscosity, ferritin, and organic phosphorus (2,3-DPG and ATP) were measured. The reversibility of the microcirculatory alterations after Ferrum Hausman therapy was followed-up. There were significant microcirculatory changes in the moderate and severe degrees of IDA consisting in the following: foci of microcongestion, microhaemorrhages, increased irregularity and undulatedness in the capillary and venular parts, single aneurysms, presence of "sludge-phenomenon" in these regions as well as enlarged diameter and reduced linear density of venules. The reversibility of the microcirculatory changes after treatment was delayed in the severe degree of IDA. Based on a reverse correlation of the severity of the microcirculatory changes with the values of blood viscosity, ferritin, and haemoglobin as well as on a direct one with the organic phosphate levels it was assumed that the microcirculatory bed in the venular and capillary parts reacted significantly in the moderate and severe degrees of chronic IDA.*

---

**Key-words:** Iron-deficiency anaemia, microcirculation, conjunctival biomicroscopy, histology, biochemistry

Incidence rate and distribution of iron-deficiency anemia (IDA) in Bulgaria among active females increases in the recent 20 years. This fact awakes authors' interest in the influence

of anaemic hypoxia in IDA on blood microcirculation (1-3). The morphological and functional analysis of microcirculation in IDA is of essential importance when considering this disease a state of tissue hypoxia resulting from reduced transport capacity of oxygen under conditions of diminished haemoglobin concentration (4,6). The microcirculatory bed presents an integral part

---

**Address for correspondence:**

Zh. Georgieva, Dept. of Propedeutics of Internal Medicine, Medical University, 55 Marin Drinov St, G-9002 Varna, BULGARIA  
E-mail: [internal@asclp.muvar.acad.bg](mailto:internal@asclp.muvar.acad.bg)

of the system of blood circulation and along with its numerous ties with the central haemodynamics it could reveal the adaptation scope of the organism towards the anaemic hypoxia in IDA with different degree of severity (7).

The objective of the present paper is to study the correlation between the severity of microcirculatory alterations, the degree of IDA and their reversibility after treatment.

## MATERIAL AND METHODS

The study covered 255 female patients with mean age of  $38,5 \pm 5,1$  years with chronic IDA and 43 healthy women with mean age of  $36,9 \pm 6,7$  years as controls. According to the haemographic parameters, patients were divided into the following groups: group one - with slight degree of IDA (51 patients); group two - with moderate degree of IDA (101 patients), and group three - with severe degree of IDA (103 patients). The following parameters were estimated in all the patients: haemoglobin concentration in peripheral blood, serum iron level, blood viscosity (by means of Hoepler rheoviscosimeter), and organic phosphate levels (after Ericson's method for 2,3-DPG (cit. after 1) with reactives of the Boehringer firm and after Duce's method for ATP (cit. after 1). Ferritin levels of all the patients were determined by the radioimmunologic method with reactives of the IRMO-FERRITIN firm. The method of con-

junctival biomicroscopy was applied to investigate the changes in the microcirculatory bed under clinical conditions (5). After photographic registration of the terminal vascular bed of the bulbar conjunctiva the qualitative-quantitative scale of Moeriche-Volkov was used. The following conjunctival indexes were determined:  $CI_1$  - of extravascular changes,  $CI_2$  - of vascular changes,  $CI_3$  - of intravascular changes, and  $CI_c$  - a cumulative index of microcirculatory changes. The average diameter of magistral arterioles and venules was estimated by means of micrometer in  $\mu m$ . The linear density of microvessels was measured by an original scale-coordinate network in  $sos/cm$ . The patients underwent a 14-day parenteral treatment with Ferrum Hausman followed by one-month peroral one. Then an evaluation of the reversibility of microcirculatory alterations was carried out.

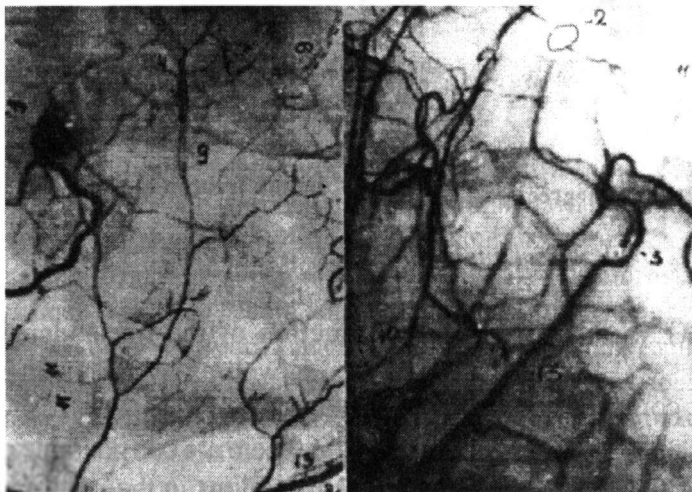
## RESULTS AND DISCUSSION

Extravascular changes in IDA patients are presented by microcongestion foci and haemorrhages while they can not be established in healthy women. Their relative share increases with advancing severity of anaemia. We agree with Hills' and Puel's concept (cit. after 4) that extravascular alterations in the microcirculatory bed of IDA patients result from disturbed vascular permeability induced by the anaemic hypoxia. After the treat-

ment and iron-deficiency compensation in the patients these disturbances fade away. Vascular alterations are manifested by changing the architectonics of both venular and capillary parts of the microcirculatory bed, i.e., with an increased undulation and irregularity of these microvessels as well as with the appearance of aneurysms in both venules and capillaries. These lesions are interpreted as an indirect evidence of dystrophic changes of the vascular wall (3). The enhanced microvascular undulatedness is considered a main manifestation of IDA at the level of terminal blood flow. In our opinion, it is a compensatory reaction of microcirculation towards the enlarged total surface of volume microvessels helping the exchange in the tissues.

Intravascular alterations are presented by changing the blood flow of both venules and capillaries and by the appearance of the "sludge-phenom-

enon" (Fig. 1). The percentage presence of this phenomenon with the severe degree of IDA is highest in postcapillary venules (54,62 per cent) and magistral venules (40,33 per cent) followed by that in capillaries (39,93 per cent). Blood flow velocity in the venular part of microcirculation is most delayed. The increasing diameter of venular microvessels in IDA delays it additionally, indeed (3,7). Correlation between the severity of anaemia and "sludge-phenomenon" presence towards haemoglobin values is  $r = 0,328$  (Fig. 2). Anaemic hypoxia with the moderate and severe degrees of IDA provokes the reduction of the linear density of venules, capillaries as well as of the total linear density of microvessels. Correlation between haemoglobin concentration and total linear density of microvessels is  $r = 0,344$  (at the level of  $p < 0,001$ ) while between haemoglobin and venular linear density it is  $r =$



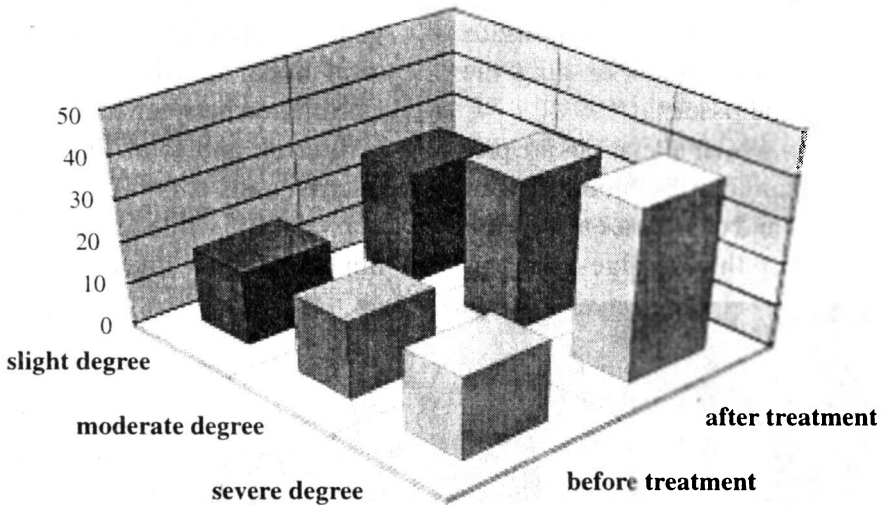
- 2-perivascular oedema
- 3-irregularity
- 4-aneurysm
- 9-"sludge phenomenon"

Fig. 1. Microcirculatory changes in IDA

0,385 (5,6).

We consider the reduction of the linear density in the venular part of microcirculation along with advancing severity of IDA a compensatory mechanism. It is directed not only towards the restoration of the total blood flow but also towards the enhancement of the venous blood inflow to the heart aiming at increasing heart minute and stroke volumes both. Microcirculatory disorders gradually aggravate along with the reduction of the values of ferritin, blood viscosity and haemoglobin concentration becoming most outlined in the severe degree of IDA. The values of 2,3-

DPG and ATP both elevate in order to compensate the anaemic hypoxia. The treatment performed induces a complete reversibility of the alterations in the slight and moderate degree of IDA while this reversibility expressed by the CI in the severe degree of IDA is delayed. The microvascular linear density undergoes a complete reversibility after treatment when the three forms of IDA are concerned. The intravascular alterations and the diameter of magistral venules with the severe degree of IDA present signs which react last to haemoglobin normalization and thus possess a delayed course of reversibility.



*Fig. 2. Intravascular microcirculatory changes in IDA*

## CONCLUSIONS

1. IDA induces a compensatory reconstruction of the microcirculatory bed manifested by an increased undulation of both venules and capillaries,

by reduction of the linear density of venules as well as by increasing their diameter.

2. There are considerable pathological alterations in the microcirculation in the moderate and severe degree

of IDA characterized by the appearance of disturbed vascular permeability and "sludge-phenomenon".

3. There is a correlation between the microcirculatory changes and the levels of haemoglobin, viscosity, and ferritin as well as the changes of organic

phosphates.

4. A complete reversibility after treatment occurs with the slight and moderate degree of IDA. There is a delayed course of reversibility when the severe degree of IDA is concerned.

## REFERENCES

1. Чернух, А. М. Некоторые проблемы взаимосвязи микроциркуляции и системного кровообращения в условиях патологии. Москва, Мир, 1995. Т. 1, 3-12.- 2. Bloch, E. N. *Invest. Ophthalmol.*, **12**, 1990, 384-398.- 3. Franco, A. L. Physiologic and Morphologic Microcirculatory Responses in Humans. Vol. 2. Blood Vessels and Circulation. Oxford, Pergamon Press, 1998, 33-37.- 4. Larcam, A., J. F. Stoltz. Microcirculation et hemomorphologie. Paris, Masson, 1998, 105-186.- 5. OrceI, L. La circulation de la conjunctive bulbaire a l'etat normal et pathologique. Paris, Flammarion, 1998, 362-373.- 6. OrceI, L., G. Chomette. Anatomie pathologique vasculaire. Paris, Flammarion, 1998, 326-348.- 7. Wells, R. The Microcirculation in Clinical Medicine. New York, etc., Academic Press, 1997, 322-329.

## Микроциркулаторни промени при болни с хронична желязодефицитна анемия

Ж. Георгиева

*Катедра по пропедевтика на вътрешните болести,  
Медицински университет-Варна*

**Резюме:** Хроничната анемична хипоксия при желязодефицитната анемия (ЖДА) обуславя съществени изменения в микроциркулаторното русло: извънсъдови, съдови и вътресъдови нарушения, както и промени в диаметъра и линейната плътност на венуларния отдел на микроциркулацията. Изследвани бяха както корелационната зависимост между тежестта на микроциркулаторните промени и степента на ЖДА, така и тяхната обратимост след лечение. Микроциркулаторното русло беше проучено с метода на конюнктивалната биомикроскопия при 255 болни жени, разпределение в групи с лека, средна и тежка степен на ЖДА. Измерени бяха стойностите на кръвния вискозитет, феритина и органичния фосфор (2,3-ДФГ и АТФ). Проследена беше обратимостта на микроциркулаторните изменения след лечение с Ferrum Hausman. Установиха се следните значими микроциркулаторни промени при средната и тежка

степен на ЖДА: огнища ма микрозастой, микрохеморагии, повишена неравномерност и нагънатост в капилярните и венулни участъци, единични аневризми, наличие на "слъдж"-феномен в тези области, както и увеличен диаметър и намалена линейна плътност на венулите. След лечението обратимостта на микроциркулаторните изменения при тежката степен на ЖДА бе забавена. Въз основа на обратната корелационна зависимост на тежестта на микроциркулаторните промени със стойностите на кръвния вискозитет, феритина и хемоглобина, както и на правата корелация с нивата на органичните фосфати се прие, че микроциркулаторното русло във венуларните и капилярни участъци реагира значимо при средната и тежка степен на ЖДА.