ECHOGRAPHIC VISUALIZATION OF THE PYELO-CALIX SYSTEM IN RENAL PATIENTS AFTER WATER LOADING

H. Sapoundjiev, D. Nenov

Key-words: ultrasonic diagnosis — pyelo-calix system — water loading

The state of the pyelo-calix system (PCS) is essentially important for the diagnosis of certain renal diseases: hydronephrosis (2, 5), pyelonephritis (1) renal tuberculosis (6), urolithiasis (1, 3), etc. However, when an obstruction i primary absent, or after its spontaneous or respectively therapeutical overcomin the PCS can't be well observed by means of ultrasonographic investigation. Th aim of the present study was to elaborate a method for better echographic visua lization of renal calices and pelvis following patients' hydratation.

Material and methods

961 patients with different renal diseases and 15 healthy persons (control group) have been studied (table 1). Half an hour after drinking 800—1000 ml water a repeated renal echotomography was carried out and the results were compared with these ones before water loading.

The echographic study was performed by using the apparatus "ECHOVU 80 L" from the firm Picker with transducer 2,25 mHz and with the apparatus "VIDOSON 735'' from the firm Siemens, too — in 11 patients only.

Table 1

Patients' distribution

Diagnosis	Number of patients	Number of patients with changes in the PCS	
		N	%
Pyelonephritis	356	342	96,0
Nephrolithiasis	298	167	56,0
Glomerulonephritis	43	37	81,3
Nephroptosis	39	24	61,5
Congenital anomalies	36	30	83,3
Ureterolithiasis	30	22	73,3
Renal tuberculosis	26	20	76,9
Hypertension	24	6	25,0
Polycystic disease	19	19	100,0
Neoplasms	16	12	75,0
Solitary cysts	16	15	93,8
Amyloidosis	8	8	100,0
Endemic nephropathy	4	4	100,0
Injuries	3	3	100,0
Others	43	43	100,0
Total	961	750	78,0

Persons with non-known end diagnosis are not included in our study. The PCS was also determined on a dog with constant venous infusion of physiological serum in an acute experiment by using the ultrasonography.

Results and discussion

After hydratation in all persons of the control group both the PCS and the parenchymal-pyelocalic index were clearly determined as 1,8±0,2. In 8 of them



Fig. 1

the intrarenal vessels can be followed up and the reflex echos of arched arteries can be better observed. No differences in the field size of the sections as contrasted with these ones after furanthril application (4) have been established.

The administration of water loading is based on the precondition that an urologic obstruction or delayed urine drainage exists in a lot of renal diseases and which can be better visualized by this way (fig. 1 and fig. 2).

The contraindications for hydratation were the same ones as in every other water loading of the organism. The hydratation doesn't alter the echographic picture in diseases with contour renal changes and with involving of the PCS (in all cases of renal tumours and polycystic disease, solitary cysts and hydronephrosis after total obstruction), respectively. In 14 cases with renal hypoplasia the characteristic proportional diminution of the PCS towards to the whole organ, which is better visible in hydratation, was established. This is in contrast to non-varying visualization in "small" silent kidneys. In 29 patients with silent kidneys the visualization of the PCS was not improved after water loading.

Certain changes in both PCS and parenchymal-pyelocalic index are established in 96 per cent of the patients with pyelonephritis. The inflammatory alterations in renal papillae and pelvis are enhanced in 128 patients after water loading.

In renal tuberculosis the hydratation helps the better visualization of the foci and accompanying inflammations, etc. In 20 from 26 patients (77 per cent) with bacteriologically proved renal tuberculosis some changes in the calices

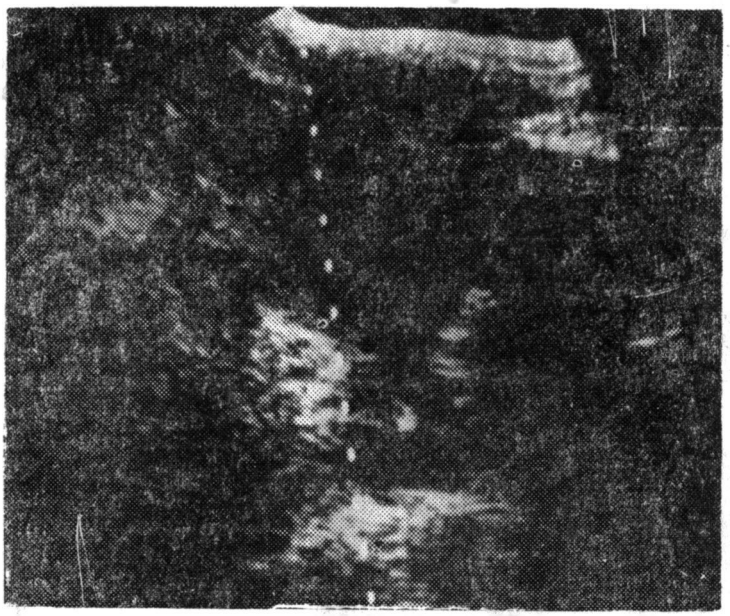

Fig. 2

(size, shape, echo-structure) and a decrease of parenchymal-pyelocalic index from 1,5:1,0 till 1:1 like this one in pyelonephritis have been found out.

The high percentage of changes in the PCS in some predominantly parenchymatous renal diseases such as glomerulonephritis, endemic nephropathy, hypertension and amyloidosis could be due to the fact that the investigation is carried out at later stage of disease when there is already a marked renal failure and nephrosclerosis.

Conclusions

1. The echographic study of renal patients ascertains some changes in the PCS at a high rate (78 per cent of the cases), indeed.
2. The PCS visualization improves significantly after water loading in case of delayed urine drainage.

REFERENCES

1. Джераси, Р. Резултати от приложението на ултразвуковата диагностика в бъбречните заболявания. — *Вътр. болести,* 1982, 1, 75—80. — 2. Coleman, B. G., P. H. Arger, C. B. Mulhern et al. Gray-scale sonographic spectrum of hypernephromas. — *Radiology,* 137, 1980, 757—765. — 3. Cook, J. H., A. T. Rosenfield, K. J. Taylor. Ultrasonic demonstration of intrarenal anatomy. — *Amer. J. Roent-*

genol., 129, 1977, 831—835. — 4. Maggiore, G., G. Curatola, C. Zoccali. Effect of Furosemide on renal size: Ultrasonic characterisation of renovascular hypertension. — *Nephron*, 31, 1982, 1, 45—60. — 5. Rolls, P. W., M. L. Emsten, S. Boger et al. Severe hydronephrosis and severe renal cystic disease: ultrasonic differentiation. — *Amer. J. Roentgenol.*, 134, 1980, 473—475. — 6. Sapoundjiev, H. Actualisation de l'echotomographie dans la tuberculose du rein. Resumes de la XVII[l] Semaine medicale balcanique Sofia, 1982, 1, 192.

ЭХОГРАФИЧЕСКАЯ ВИЗУАЛИЗАЦИЯ ЧАШЕЧНО-ЛОХАНОЧНОЙ СИСТЕМЫ У БОЛЬНЫХ ПОЧЕЧНЫМИ ЗАБОЛЕВАНИЯМИ ПОСЛЕ ВОДНОЙ НАГРУЗКИ

Хр. Сапунджиев, Д. Ненов

РЕЗЮМЕ

Проведено ультразвуковое исследование почек у 961 больного различными почечными заболеваниями. При применении этого метода у 750 (78 %) больных были обнаружены изменения чашечно-лоханочной системы. После водной нагрузки с соблюдением общепринятых требований улучшается определение кортико-ренального индекса внутри- или внепочечной части лоханки. Визуализация чашечно-лоханочной системы лучше при заболеваниях с замедленным дренажем мочи. Контрольная группа состаяла из 15 здоровых лиц. Был проведен острый эксперимент на собаке после водной нагрузки инфузией физиологической сыворотки.