UPON SOME PECULIARITIES OF STRUCTURE AND VASCULARIZATION OF SUPERFICIAL AND PROFOUND CRURAL VEINS

G. Marinov

The problem of the anatomical variations of the superficial and profound veins of lower extremities reveals out certain scientific interest due to the fact that the clear knowledge of these differences will undoubtfully assist the physiology, pathology and plastic surgery of the veins in this region. Our aim was to investigate the differences of structure and vascularization of the wall of magistral veins in the region of the crus because these veins are part of a functional system which is the usual predilectional localization of any varicosal and thrombophlebial disorder; the latter is a very often object of the plastic surgery. Their surroundings allow suitable possibilities to study the vein wall under various functional conditions. Our investigation tends to add some more information about this question because in the available literature we find out certain insufficiencies or contradictory comments by many authors. We also tend to investigate in details the problems of this region first studied by V. Vankov (1968) but concerning some other veins and anatomical zones.

Materials and methods

The structure of the vein wall was studied on histological cuts stained by haematoxylin-eosin, orcein and after van Gieson. 216 preparations of 26 individuals, aged 0—81 years were under our study. The vascularization of the vein wall was studied after an injection with a contrast mass of china-black gelatin in the vessel intramural tract (prescription of V. Vankov, 1968; 1974). Total bright histological preparations were made of 147 objects of 19 ndividuals, aged 0—81 years.

Results and discussion

The structure of the walls of magistral veins of the crus is not enough investigated. There are no information about the age, local and regional peculiarities of the posterior tibial and small saphenous veins. More often the great saphenous vein has been the object of study, but nevertheles its crural region is not sufficiently analysed. Our data show that the walls of these veins are based on a common structural plan. In new-born individuals they consist only of circulatorily orientated muscles distributed in their media (fig. 1). Their elastic fibres form a space sceleton which is more dense under endothelium, thus forming a thicker internal set. With age the structure of the vein wall undergoes certain changes. The amount of the muscle mass increases considerably. This is a direct result of the thicker circulatory muscles of the media, as well as of the new-formed muscle layers — longitudinal or circulatory

in the intima and only longitudinal in the adventitia (fig. 2, 3). The internal elastic set is more dense and by its consistence it is almost like a real membrane. The three investigated veins, however, show certain individual peculiarities in structure and muscle amount, in distribution of the fibres, dyna-



Fig. 1

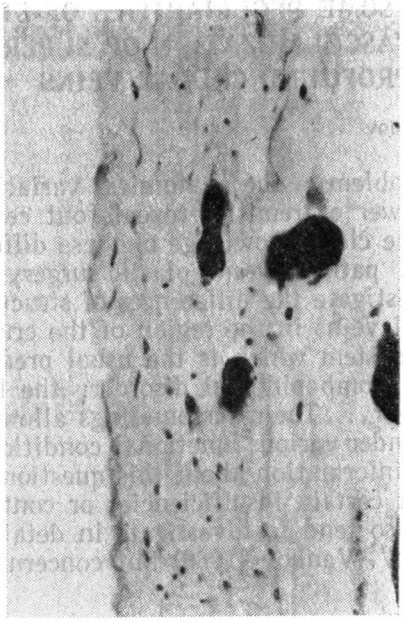

Fig. 2

mics of new-formed and development of new fibres and layers in the intima and adventitia. The muscle layer of the small saphenous vein reaches its largest thickness and is ordered in 4 layers (sublayers). The wall of the great saphenous vein is not so thick and 4 sublayers are rarely detected. The muscle layer is thinest in the wall of the posterior tibial vein and maximum number of muscle sublayers is 3. Concerning this vein, longitudinal muscle fibres are formed latest in comparison with the superficial ones and even there are cases when such fibres simply do not appear until late age. These individual peculiarities are rather interesting because as for the cited 2 saphenous veins there are only a few articles in the available literature concerning their forth muscle sublayer. Very important feature of the profound veins, specially the posterior tibial one, is the fact that the thickness of the wall is not equal in all zones. For example, in this part of the vein where it is attached to the same-name artery the muscle mass of the wall is 50% thiner and it is very often represented by only one muscular layer — the circulatory one in the media. This is a very important fact, specially concerning the plastic surgery. The cited peculiarities of the investigated vein walls can be directed to the rules formulated by V. Vankov (1968; 1974) that the thickening of the muscle layers is usually accompanied by a more complex setting and adding of new muscle fibres.

The available literature does not give enough information about the question of the vascularization of the walls of the magistral crural veins; fur-

thermore, the data are quite contradictory due to the numerous methodological difficulties. No one of all authors studied the aforementioned problem: Golovinskii (1945); Zimmermann (1950); Khomakhidze (1955); Akilova (1956); Beljanskii (1958); Lang (1961), was capable of proving the real anatomy of

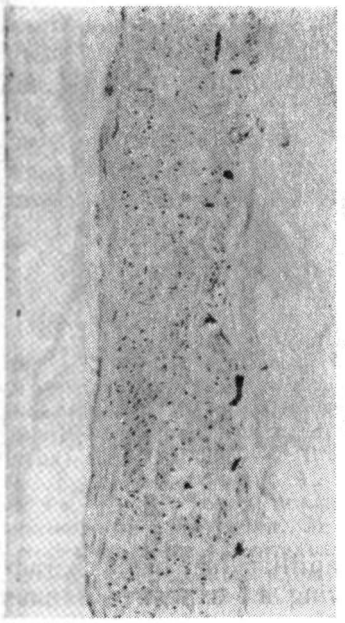

Fig. 3

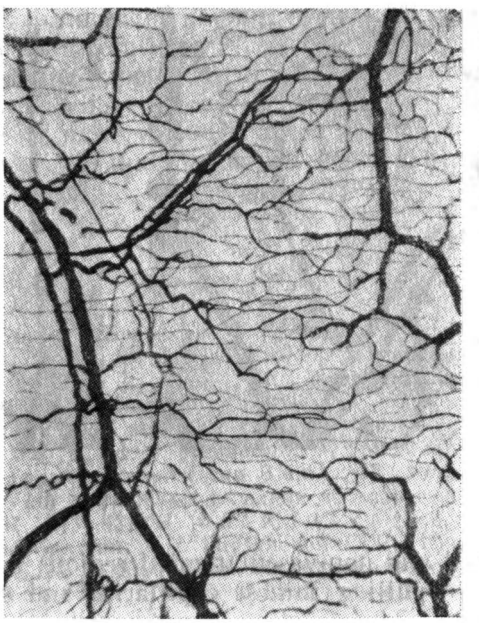

Fig. 4

the intramural vessel tract. By applying our suitable technique we succeeded to demonstrate the full intramural capilliary set. Therefore, we investigated the unknown question of its angioarchitectony and relations with the structural elements of the vein wall. Our data show that superficial and profound crural veins have same and equal plan of vascularization. A space capilliary set is formed in them; it lays in the muscle layer and vessel split located in the adventitia (fig. 4). The vessel split is formed by arterial and venous vessels with different order; between them there are numerous and various formed anasthomosa — interarterial, intervenous and arterio-venous (fig. 4). The cited type of formation proves that the adventitial vessel split possesses a transport and distributive (for the intramural blood-current) importance. The space capilliary set is formed as an example of mainly nutritive type. There can be established direct communications between pre- and post-capillaries, being of the type of arterio-venous bridges in other zones (Zweifach, 1939; 1957). All that shows that here is performed a fine regulation of the intramural blood-current (fig. 5).

Any of the studied by us veins has its individual features, concerning its vascularization. The muscle layer of the walls of great and small saphenous veins is always well vascularizated (fig. 1, 2, 4). As for the walls of the anterior and posterior tibial veins there is a certain variation between well vascularizated and even vesselless zones (fig. 3, 5, 6). This fact is rather important

because according to Beljanskii (1958) it is accepted that these veins are vascularizated only in the region of the adventitia, which, obviously, is valid for a little part of their wall. Quite often there exist no vessels in the zones where profound veins are attached to their same-name arteries. In the interzones of

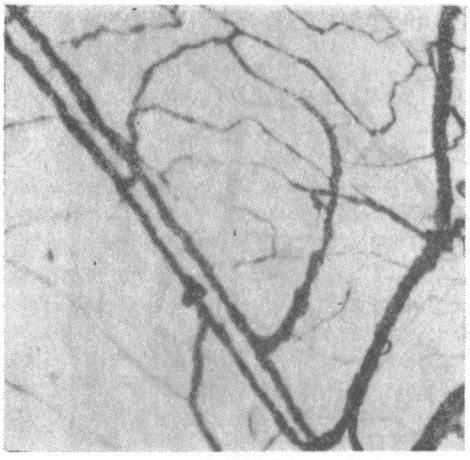

Fig. 5



Fig. 6

vascularizated and non-vascularizated regions the capilliary set has a characteristic end — pulling thinest capillaries and showing an expressed venous type (fig. 6).

The interrelations between intramural vessel tract and structural elements of the wall are characterized by Bastide, Juskiewenski and Roullea (1966) as "big problem" of the question of vascularization of the vessel wall. Our data show that the capilliary set of all investigated veins is structurally based in the region of the middle circulatory muscle layer which determines its transversal orientation (fig. 1, 2, 3). As an exception it can enter the inner longitudinal muscle layer. It is interesting that in new-born individuals the capilliary set is based diffusively in the only one single muscle layer (circulatory) and its capillaries go very near to the vessel's lumen (fig. 1) which considerably differs from the opinion of certain authors (Khomakhidze, Beljanskii, Etcha) saying that in new-borns the muscle fibres have no vessels, even convincing that this fact is valid for all veins. In the process of the development of the organism the capillary set decreases its density several times — 8—10 times (fig. 2, 3) and the most profound capillaries go far from the vessel's lumen, thus forming an inner avascularizated muscle layer with an average thickness in old individuals about 70—85 micrometers (fig. 3). These changes are analogous with those of the femoral vessels reported first by V. Vankov (1965).

The reasons for formation of avascularizated zones in the walls of the profound veins are still not enough revealed out. Our data show that they are a result of thinning of the muscle mass. When studying the interregion between avascularizated and vascularizated zones we establiash that the first capillaries enter the muscle layers only when their thickness is over 6—8 micrometers in new-borns or 70—90 micrometers in older individuals, i. g. the thickness of the inner avascularizated laye r of the rest length of the vein. Due to

these facts we presume the cited thickness as critical concerning the wall vascularization.

Based on our study we can conclude and analyse the influence of the topography-anatomical morphology upon the structure and vascularization of the crural vein walls. As the surrounding masses play a supportive role of the profound veins their wall becomes thinner, the amount of muscle fibres decreases, their muscle layers reduce and as a result some of them become avascularizated. The surrounding masses of the superficial veins does not create a considerable outer support. Due to this fact their wall, respectively their muscle layer, is rather thicker, possesses more variously orientated layers and is vascularizated in a higher degree. All that makes the superficial veins quite more suitable for a plastic material.

REFERENCES

1. Акилова, А. Т. *Вестник Хирургии им. Грекова.*, М., 1956, 77, 9, 73—85. — 2. Белянский, В. А. Труды VI Всесоюзного съезда анатомии, гистологии и эмбриологии. Киев, 1958, 1, 35—39. — 3. Ванков, В. Н. Тезисы докладов II конференции анатомии, гистологии и эмбриологии. С., 1965, 61—62. — 4. Ванков, В. Н. Строение и васкуляризация стенки вен и их клапанов. Дисерт. д. м. н. Ленинград—Варна, 1968. — 5. Ванков, В. Н. Строение вен., М., Медицина, 1974, 138. — 6. Головинский А. И. Труды научной сесии ВММА., Л., 1947, 18—21. — 7. Еча, Г. Я. Тезисы докладов VIII научной конференции по возрастной морфологии, физиологии и биохимии., М., 1967, 4, 1, 93—94. — 8. Комахидзе, М. Э. Труды Института Экспериментальной морфологии. АН Грузинской ССР. Тбилиси, 1955, 5, 60—63. — 9. Циммерман, С. Э. Сборник работ Ставропольского медицинского института, 1950, 43—58. — 10. Bastide, G., S. Juskiewenski, J. Roulleau. *C. R. de l'Assoc. Anat.,* 134, 1966, 150—156. — 11. Lang, J. *Z. Anat.,* 122, 1961, 482—517. — 12. Zweifach, B. *Anat. Rec.,* 73, 1939, 475— 13. Zweifach, B. *Ann. J. Med.,* 23, 1957, 684—696.

О НЕКОТОРЫХ РАЗЛИЧИЯХ В СТРУКТУРЕ И ВАСКУЛЯРИЗАЦИИ ПОВЕРХНОСТНЫХ И ГЛУБОКИХ ВЕН ГОЛЕНИ

Г. Маринов

РЕЗЮМЕ

Полученные автором результаты показывают, что поверхностные вены голени (v. saphena magna et v. saphena parva) и глубокие вены голени (v. tibialis ant. et v. tibialis post) значительно различаются по некоторым особенностям мускулатуры и элластических волокон их стенки. Стенки поверхностных вен отличаются лучшим развитием мускулатуры. Их мышечный слой более утолщенный; он образует до четырех различно ориентированных слоев. Мышечный слой глубоких вен образует до трех таких слоев. Кроме того, в стенках глубоких вен обнаруживаются аваскулярные зоны, в то время как стенки поверхностных вен всегда хорошо васкуляризованы. Указанные различия свидетельствуют об определенной зависимости от возраста индивида.