

SUCCESSFUL RESUSCITATION AND REHABILITATION OF A CHILD FROM THE STATE OF CLINICAL DEATH (CARDIAC ARREST), CAUSED BY NOVOCAIN INTOXICATION

Z. Kisiov, L. Belchev, E. Bozadjieva, N. Kiuchukov, Vl. Ivanov and D. Shelyazkov

Cases of cardiac death (cardiac arrest) caused by local anesthesia with novocain are rarity. According to *Waters Jimms* — 1944 (cited by 6), clinical death accidents during local anesthesia are encountered in 0,106%. They are mostly casually related to hypersensibility and intolerance to novocain. Exceedingly rare are the instances of cardiac arrest, caused by novocain intoxication.

Recently, we had the possibility to observe resuscitation of a child from clinical death by novocain intoxication, as well as its subsequent successful rehabilitation.

On 12 September, 1964 in the Naval Hospital at Varna, the patient N. J. J., 9-year-old schoolboy (case history 845/12. IX. 1963) was admitted for tonsillectomy. Erroneously, peritonsillar anesthesia was carried out with 10% instead of 1% novocain solution, totalling a quantity of 40 ml. About 5 min after the anesthesia the child sustains heavy epileptiform fits with loss of consciousness. Breathing is gradually delayed, becomes superficial and in 1—2 minutes it ceases completely. Several minutes later heart activity is also arrested. Dilatation of the pupils is established and reaction to light disappears. The eyeballs are softened. Full areflexia (absence of reflexes) occurs. Epinephrine, luminal, caffeine, cardiazol, plegomazin, nor-epinephrine and cortisone are administered by injection. On the 4—5th minute of cardiac arrest, the child is intubated, and after further 5 min, leftside thoracotomy and direct heart massage performed. On opening the chest cavity, the heart is found relaxed in diastole, filled up with blood. The wound is not bleeding. After nearly 40 compressions (pumping), independent cardiac activity is resumed. Blood pressure is increased up to 120/80 mm of Mercury column, the pupils are contracted. Pupillary reaction to light is restored. An hour later spontaneous breathing occurs, initially weaker and superficial (28—30 respirations per minute) and subsequently, though speeded up — with adequate depth and effectiveness. Twenty four hours later extubation is resorted to and tracheostomy applied. The operative wound of the thorax heals by first intention and no pulmonary complications occur.

After restoration of heart functioning and breathing, the child remains in the state of deep coma, with narrow and slowly reacting to light pupils and central fixation of eyeballs. At this stage the reflexes of the lower limbs are pathologically intensified with expanded reflexogenic zone. Babinski —

positive bilaterally. Upper limb reflexes and abdominal reflexes are lost. Occasionally, transitory tonic contractions are noted — extensor for the lower and flexor for the upper limbs, accompanied at times by clonic tremors of the right hand. Involuntary discharge of urine is observed from time to time.

During the following days, breathing is regular, deep and frequent (28—30 per min), cardiac activity is rhythmic, accelerated (120 beats per minute), blood pressure 120/80. On the third day the child sustains hyperpyrexia with concomitant pulse rate retardation, whereas blood pressure shows a propensity towards falling. Hyperpyrexia necessitates the placing of ice-packs in the large blood vessels' areas.

In the fundus oculorum alterations are not disclosed. In the state of complete and deep coma the child remains for 10 days and subsequently, with some fluctuations and recurrent deteriorations, the child gradually passes in deep sopor, remaining in this state up to the end of the second post-accident month.

During the period of deep coma the child persists with tonic convulsions, more strongly manifested in the upper limbs. Occasionally, against the background of general tonic convulsions, lasting clonic tremors are noted of the right hand. Spasm of masticatory musculature occurs developing pronounced trismus. Tonic convulsions are usually provoked by moderate mechanical irritations. During the convulsions erection of the penis is observed. Later on, torsion convulsions are also added to the decerebration phenomena. Gradually the hands assume permanent flexor contracture position, and the legs — extension contracture. These manifestations are more pronounced on the rightside limbs. Rigidity of the neck musculature is also marked. The pupils on the left are dilated with slight reaction to light, and on the right — considerably narrowed, but with adequate light reaction. On the rightside the Babinski sign is positive.

On the 10th post-accident day, for the first time, following external irritation, the child begins to utter groans and shed tears; on the 20th day, in the periods free of luminal effect, the child makes attempts for waking up with opening of both eyes.

The convulsive seizures and convulsive susceptibility gradually subside. A tendency is observed towards localization of the convulsions. The pharyngeal reflex is restored. On stimulation the child commences to react with nausea, vomiting appeals and coughing. It makes attempts for emitting single sounds. When irritated it moans. Nevertheless, periodically rather frequent convulsions are observed — flexor for the upper limbs and extensor — for the lower. To painful stimulations it responds with subcortical emotional reactions and withdrawal of the limb. Gradually, it begins to direct its look and to react to sound and light stimulants. To the attempts for mobilization of the limbs it reacts with convulsions and crying.

On the 28th day from the accident it is impossible to establish contact with the patient regardless of the daily improvement of the condition. The hand continue to be flexed to the chest. The wrists and fingers of both hands are also in flexion contracture. The lower limbs are flexed at the knee joint with feet in plantar flexion, similar to the Turkish „crossed-leg“ mode of sitting (Fig. 1). Breathing and pulse rate are completely normalized. Blood pressure 120/75 mm of Mercury column. Hyperthermia however, persists

till the end of the second month. At this time the child for the first time follows his mother with eyes.

Later on, the flexion contractures of the limbs are gradually overcome by means of slow and carefully executed traction. Abdominal reflexes are regained as well as tendinous and periosteal reflexes, which are pathological

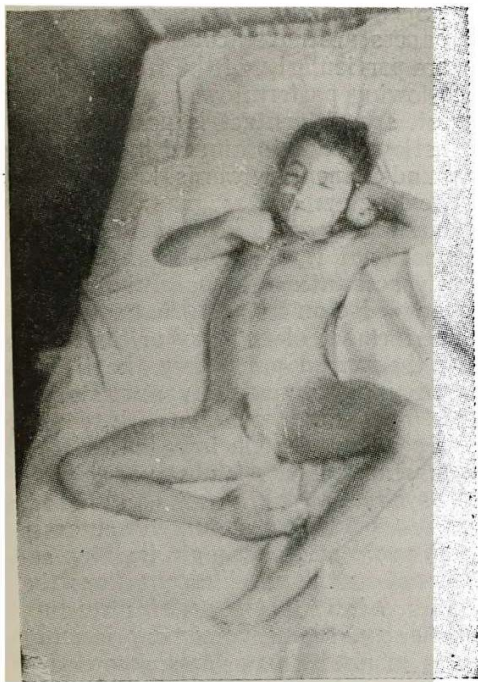

Fig. 1




Fig. 2

intensified. The child begins to make attempts for voluntary control of the sphincter ani and sphincter urethrae, tries to speak, but his speech is dysarthric. Nutrition with probe through the nose is discontinued and substituted by oral feeding.

After nearly two months from the onset of the accident, active treatment is undertaken with muscle relaxants, baths, slight careful massage and mobilization of the extremities, initially under-water at temperature 37,5 — 38°C, and subsequently without bath.

Gradually, as a result of treatment as well as logopedic and pedagogic education, motor and psychic activity is improved. The contractures become milder.

Towards the end of February, after 3 ½ months of actively carried out physical therapy, the neurological state of the child is almost completely restored in many respects. The child is able to stand up freely and without assistance, to sit down, to move, to go up and down stairs, to ride bicycle,

to dress and undress as well as to feed himself alone (Fig. 2). Writing is still unattainable. Latent pareses are not established. The contractures have disappeared, a slight flexion contracture persisting only of the ring and small finger of the right hand. Tendinous and periosteal reflexes are moderately alive, slightly more pronounced on the left. Abdominal reflexes are present. During carrying out the nose-indicating test, intentional tremor is marked of the right hand only. Speech is slightly aphonic, but not dysarthric. Aphasic and apraxic disturbances are not encountered.

The restoration of the psychic and more particularly, of the second signal system of the child is effected in the following pattern: towards the end of the second month from the cardiac arrest, speech contact is possible. The child begins to answer adequately to questions made to him with „yes“ and „no“, as well as to utter single syllables and elementary words, learnt in the earliest years of life, during the ontogenetic development, as „mam“, „daddy“ and so on. It begins to recognize its relatives and to display adequate in type, but quantitatively actually expressed emotional reactions — laugh when teased, terror when massaged (doubtlessly accounting for painful feeling). During the following week some of the knowledge on its past life experience is gradually regained. It is capable of performing elementary arithmetical operations. Gradually the memories for the period preceeding the illness are restored, a rather limited period remaining dimmed by amnesia, in which erroneous memories are included (retrograde amnesia with confabulation). Fixation of new impressions is possible, though impeded (partial Korsakoff's syndrome). Bradipsychia is present, grimace is observed, obviously, of involuntary nature. Increased psychic fatigability is established, and active attention is engaged for short time, with pronounced acuteness of passive attention. In the course of logopedic and pedagogic training sessions, the child exhibits rapid improvement in the psychic condition: the reserves of past knowledge are restored in a substantial extent; reading however, is embarked on with some difficulty. Fixation memory is more and more improved, and the child begins to master new ideas, knowledge and conceptions. The initial sluggishness is gradually substituted by constantly gaining strength motor and speech voluntary activity.

Following the phase characterized by rather quick improvement, a period of nearly two-month duration ensues of staleness in the further rehabilitation and development of psychic activities, followed a second time by a period of substantial restoration: the elements of the Korsakoff's syndrome completely subside and the patient is capable of fixing in very satisfactorily new impressions (anterograde amnesia naturally persists for the comatose period). Psychic capacity is greatly improved. Active attention is maintained for prolonged periods (in spite of the still existent acuteness of passive attention). The child is considerably more alive. The presence of certain degree of bradipsychia persists, manifesting itself mostly during intellectual activities, in which largely restricted capabilities are established.

In the case clinical death (sudden cardiac standstill) is undoubtedly concerned, caused by novocain intoxication. The child received about 40 gr novocain in the peri — and retrotonsillar space — a quantity exceeding several times the lethal dose of this drug in humans, equivalent to 30 mg per kilogram body weight during subcutaneous injection (9). Considering also the circumstance that in this case a concentrated novocain so-

lution (10%) is concerned, introduced in tissues with high resorptive capacity, it is more readily understood that for the manifestation of novocain toxicity, virtually, the most favourable conditions were present. And in fact, in the beginning the child exhibits the typical for novocain intoxication clinical picture — clonic convulsions followed by central paralysis of respiration and vasomotor systems. In the state of clinical death (cardiac arrest) the child remains for more than 10 minutes. Resuscitation is achieved by means of controlled breathing and direct heart massage.

Following resuscitation from cardiac arrest, the child survives in the state of deep coma for 10 days passing subsequently into the state of deep sopor for about 50 days. Massive and continuous luminal therapy (imposed by the convulsive phenomena) on its turn intensifies and prolongs the comatose condition. The deep coma in this instance is the expression of complete retention of cortical activity and that of the nearly subcorticalis.

After rehabilitation from the state of decerebration, firstly the non-conditioned reflexes are regained and next — the basic psychic functions connected with the subcortical activity (emotional reaction of unconditioned stimulants). Later on, the conditioned reflexes are resumed — firstly the function of the first signal system (emotional reaction to social stimulant), and subsequently — of the second signal condition relationships (those formed in the earliest period of life being relieved first of all). Ultimately, the intellectual-mnemonic functions are repaired, but anyway, even after full regaining of memory, the intellect is not completely restored. The function of the pyramidal system and coordination are restored rather slowly and irregularly.

Cases with so long an impairment of consciousness following resuscitation from cardiac arrest (coma and sopor for a duration of 2 months) are not encountered in the literature survey. Experience gained to date shows that the comatose state following resuscitation from cardiac standstill, lasting more than 6—12 hours, are with poor prognosis inasmuch life and rehabilitation is concerned. With the case described by *Deredjian* (2), despite the comparatively short-duration coma (48 hours), complete psychic rehabilitation was not achieved following resuscitation from the state of clinical death and regardless of the rapid restoration of functions of the nervous system — a residual Korsakoff's syndrome persists (according to personal communication by *P. Ovcharova*). The patient reported by *Krastinov* and assoc. (3), resuscitated from clinical death 25 minutes after the onset, similarly sustains complete coma with convulsions, but dies on the 14th day thereafter without regaining consciousness. On dissection the cerebral edema was found moderately manifested, while degeneration phenomena of the cerebral tissue were severe. Contrary to the two cases just referred to, our patient was relieved from the comatose state notwithstanding its exceedingly long continuity. With the latter the Korsakoff's syndrome was similarly marked, but not so massively pronounced and subsiding rather promptly.

The deep and prolonged coma in our instance was initially ascribed to heavy degenerative alterations in the cerebral tissue, occurring consequent on novocain intoxication and long-duration cerebral anoxia, caused by the cardiac arrest. Recovering from coma and regaining of nerve-psychic functions show that in the instance discussed the coma occurred as a

result mainly of beyond threshold protective retention of cortical cells, provoked by the novocain effect. It is probable that the latter played a preventive role also with respect to cerebral anoxia during the clinical death. In addition, it should be pointed out that: in the organism the procaine is inactivated via enzymic hydrolysis, effected by the procaine estherase — a ferment found mainly in the liver and identified by certain authors with the pseudocholinesterase. As a result of the procaine hydrolysis, paraaminobenzoic acid and diethylaminoethanol (8, 9) are produced. Whereas the greater part (about 80%) of the paraaminobenzoic acid is being emanated with the urine unchanged or in the form of paired compounds, the larger part (about 70 %) of diethylaminoethyl alcohol undergoes further metabolic transformations. Being not indifferent agents pharmacologically, it is probable that their effect exerts favourable influence on the process of novocain intoxication. This possibility, naturally, would have assumed a more important role in instances similar to the one herein reported, provided the quantity of procaine administered was greater and the acute fatal phase of intoxication was overcome in one way or another.

Our case demonstrates that not invariably and not in all instances of cardiac standstill (clinical death) the generally accepted tenets for resuscitation are valid — within 3—5 minutes (5). The possibility is not excluded for successful rehabilitation following cardiac arrest provoked by other factors as well.

REFERENCES

1. Атанасов А., П. Абаджиев — *Анестезиология*, С., Мед. и физик., 1963.
2. Дереджян А. — *Хирургия*, 14, 10, 915, 1961.
3. Кръстинов Г., Ев. Кръстева, Ст. Филипов, П. Кюприбашев — *Научна сесия на ВВМ* — С., Държавно военно издателство, 2, 1962.
4. Натов Г. Е., М. С. Седов — *Сердечно-сосудистый колапс во время операции*, М., Медгиз, 1961.
5. Неговский В. А. — *Оживление организма и искусственная гипотермия*, М., Медгиз, 1960.
6. Саев Ст. — *Клинична смърт в условията на хирургическата работа*. Дисертация, София, 1962.
7. Шмит В., Ж. Кудас — *Восстановительная хирургия сердца и сердечной сорочки*, М., Медгиз, 236—266, 1961.
8. Goodman L., A. Gilman — *The Pharmacological Basis of Therapeutics* — McMillan Company, New York, 1955.
9. Haenschild F. — *Pharmacologie und Grundlagen der Toxicologie*, Leipzig, 1960.
10. Schramel R. J. — *Cardial Arrest — Current Therapy*, W. B. Saunders Company, Philadelphia and London, 127, 1964.

**УСПЕШНОЕ ВЫВЕДЕНИЕ ИЗ НАСТУПИВШЕГО ВСЛЕДСТВИЕ
ОТРАВЛЕНИЯ НОВОКАИНОМ СОСТОЯНИЯ КЛИНИЧЕСКОЙ СМЕРТИ
РЕБЕНКА И ВОССТАНОВЛЕНИЕ ЕГО**

*З. Кисьов, Л. Белчев, З. Бозаджиева, Р. Койнов, Н. Кючуков, Вл. Иванов,
Д. Желязков*

Р Е З Ю М Е

При погрешном инъектировании (с целью местной анестезии при тонзиллэктомии) 40 мл 10%-ного раствора новокаина 9 лет мальчику наступила острая интоксикация с тоническими и клоническими судорогами, параличом дыхательной и сердечной деятельности. Мальчик оставался в состоянии клинической смерти более 10 минут и выведен из этого состояния с помощью управляемого дыхания и прямого массажа сердца. Последовало глубокое коматозное состояние в продолжение 10 дней, а затем в течение 50 дней состояние глубокого сопора. При восстановлении обнаружен частично выраженный синдром Корсакова, которые впоследствии исчез, тяжелая церебрастения, пирамидные и координационные нарушения. Через 6 месяцев наступило очень хорошее, но все еще неполное восстановление.