

PRINCIPLES OF SURGICAL TREATMENT OF CHRONIC POST-INTUBATION LARYNGOTRACHEAL STENOSIS IN CHILDHOOD

Vyacheslav Vavin, Ibragim Nazhmudinov, Tatyana Garashchenko, Dmitry Polyakov,
Kamila Magomedova

FSBI Scientific and Clinical Center of Otorhinolaryngology of the FMBA of the Russian Federation, Moscow, Russia

ABSTRACT

INTRODUCTION: Post-intubation stenosis of the larynx and trachea in childhood increases annually. This is associated with an increasing number of children with severe pathology of the upper respiratory tract, as well as children requiring artificial ventilation for other reasons. Until now there have been debatable questions about surgical tactics in children with chronic cicatricial laryngeal stenosis.

AIM: The aim of this article is to evaluate the effectiveness of different tactics of surgical treatment of children with chronic cicatricial post-intubation stenosis of the larynx, depending on the state of the cartilaginous frame of the larynx.

MATERIALS AND METHODS: We have treated 47 children with chronic cicatricial post-intubation stenosis of the larynx. Preoperative examination included endoscopy and computed tomography of the larynx and trachea. We assessed the cartilaginous framework of the larynx and trachea that influenced the choice of surgical approach. For 20 children with intact laryngeal cartilaginous frame the method of endolaryngeal microsurgery using a CO₂ laser was applied. This method allowed to form a wound surface by minimum submucosal resection scar tissue, which made it possible to cover the wound with mucosal microflaps to prevent restenosis. In the surgical treatment of extended stenoses of the middle larynx, there are prerequisites for repeated replacement of the wound with excess scar tissue, which in our observations was avoided by using endoprotheses for a period of 21 days. Despite it, with a lesion of the subglottic part of the larynx, the risk of restenosis remained quite high (5 out of 12 patients), even in the absence of data for damage to the cartilaginous frame of the larynx. In 27 cases of chronic post-intubation cicatricial stenosis of the larynx, in identifying of laryngeal cartilage framework lesion before surgery, extralaryngeal laryngotracheoplasty was performed. Laryngofissure was performed in 18 children, followed by stenting from 6 to 18 months with a T-shaped silicone stent, in 9 cases—one-stage laryngotracheoplasty using auto-cartilage grafts. The applied techniques have shown high efficiency, while the use of autografts made it possible to reduce the stages and duration of surgical treatment.

CONCLUSION: The use of a CO₂ laser in combination with balloon laryngoplasty in microsurgical treatment of chronic post-intubation stenosis of the larynx in children significantly expands surgical capabilities due to high accuracy and low level of damage of surrounding tissues.

Keywords: chronic laryngeal stenosis, complications of tracheal intubation in children, larynx microsurgery, CO₂ laser, laryngotracheoplasty, cartilage autografts, children

Address for correspondence:

Vyacheslav Vavin
Clinical Department of Upper Respiratory Pathology
FSBI Scientific Clinical Center for Otorhinolaryngology
FMBA of Russia
30 Volokolamsk Highway, Building 2
123182 Moscow
Russia
e-mail: lor42@mail.ru

Received: June 3, 2021

Accepted: June 20, 2021

INTRODUCTION

Among the variety of etiological factors in the development of chronic laryngeal stenosis in children, at present the main reason (up to 80%) is prolonged intubation of the larynx and trachea (1–4). In addition, in recent years, the number of tracheotomies for children with severe pathology has been increasing (5).

The development of microsurgery for laryngo-tracheal stenosis is aimed to reduce the duration of treatment and rehabilitation, taking into account not only the restoration of the respiratory tract but also the voice function of the larynx (5–7).

Despite the experience in the surgery of cicatricial stenosis of the larynx all over the world, at the moment there are no clear criteria for the use of existing techniques, the access choice (external or endoscopic), the need to use plastic materials, stents, additional equipment (laser, coblator, radio wave, etc.). As a rule, the decision is made by the surgeon based on his own experience and available equipment (8–12).

The undoubted advantages of using a CO₂ laser with an operating microscope are microsurgical accuracy, good intraoperative detailing and a dry surgical field, as well as good functional outcomes in terms of swallowing and speech with the functional results exceeding those from traditional surgical approaches (13–15).

The development of optimal surgical and rehabilitation tactics for cicatricial post-intubation and post-tracheostomy stenosis, improvement of laryngo-tracheoplasty techniques and resection techniques are currently the most important problems in laryngeal surgery in children (16).

AIM

The aim of this article is to evaluate the effectiveness of different tactics of surgical treatment of children with chronic cicatricial post-intubation stenosis of the larynx, depending on the state of the cartilaginous frame of the larynx.

MATERIALS AND METHODS

A total of 47 children with chronic cicatricial post-intubation stenosis of the larynx, in the period from 2016 to 2020, were included the study.

All patients in the preoperative period underwent endoscopic examination in the form of fibrolar-

yngotracheoscopy and CT of the larynx. According to the results, 2 groups were formed. Group 1 consisted of 20 children in whom at the preoperative stage there was no lesion of the integrity of the larynx and trachea frame. In this group the CO₂ laser was chosen by the endolaryngeal microsurgical method with direct suspension laryngoscopy, which in some cases was supplemented with balloon laryngoplasty or stenting. The age of the children in this group was from 1 to 14 years (average age 4.5 ± 2.3 years). Seven patients had a tracheostomy for a period ranging from 1 to 6 years. Analyzing the duration of the previous intubation, it was found that it lasted from 10 days to 3 months. The duration of the disease was from 8 months to 6 years and averaged 34 months (2.4 years). The reasons for intubation were cardiovascular surgery followed by intensive therapy in 5 cases, abdominal surgery in 4 cases, pathology of the central nervous system in 3 cases, acute infectious stenosing laryngitis in 4 cases, thermotrauma—in 3 cases, and poisoning—in 1 case. According to the data of preoperative examination, subglottic localization of stenosis was the most frequently observed (12 patients), the middle part of the larynx was involved in the cicatricial process in 7 patients, the vestibular part of the larynx—in 1 patient. Patients with 2nd–3rd degree of stenosis according to the Mayer-Cotton classification prevailed (Table 1).

Interventions using total intravenous anesthesia and muscle relaxation were carried out. Direct suspension laryngoscopy was performed (using the Karl Storz kit), followed by examination of the larynx using rigid endoscopes with 0-, 30-, and 45-de-

Table 1. Characteristics of children with chronic cicatricial post-intubation stenosis of the larynx from Group 1

Localization	Mayer-Cotton Degree of Stenosis			Tracheostoma
	I	II	III	
Vestibular (n = 1)		1		1
Glottic (n = 7)	1	4	2	2
Subglottic (n = 12)	2	6	4	4
Total: 20	3	11	6	7

gree optics to obtain a complete detailed picture of the length and configuration of the stenosis.

This was followed by microlaryngoscopy using an operating microscope and surgical intervention using a surgical CO₂ laser equipped with a micromanipulator and integrated with a microscope in the superpulse operating mode, with a power from 3 to 8 W. In cases of actions in the region of the distal trachea, which are difficult to access for work under a microscope, endoscopic control was used using a CO₂ laser transmitted through a glass fiber. The power parameters and the shape of the beam were selected based on the required depth and area of action.

Group 2 consisted of 27 children in whom the preoperative examination revealed a lesion of the laryngeal cartilaginous frame (Fig. 1). They underwent reconstruction of the laryngeal cartilage and restoration of the stable lumen of the larynx by extralaryngeal access with the replacement of the lost laryngeal structures with cartilaginous autografts.

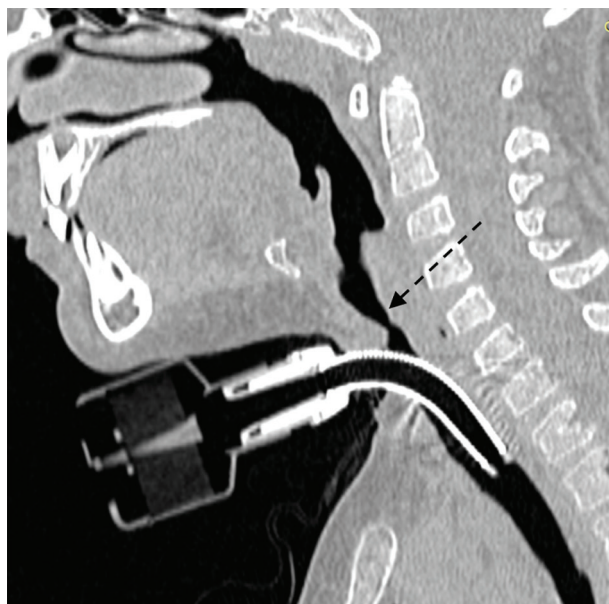


Fig. 1. Violation of the cartilaginous framework of the larynx and trachea revealed by CT

The age of children in this group was from 2 to 14 years (average age 9.4 ± 4.2 years). All patients had a tracheostomy for a period ranging from 1 to 9 years. Analyzing the duration of the previous intubation, it was found that it lasted from 10 days to 3 months. The duration of the disease was from 11 months to 9

years and averaged 51 months (4.3 years). The reasons for intubation were cardiovascular surgery in 4 cases, abdominal surgery in 2, pathology of the central nervous system in 5, acute infectious stenosing laryngitis in 14 cases, and thermotrauma in 2. According to the preoperative examination, it was found that the localization of the lesion was dominated by the subglottic part of the larynx (24 patients), and the glottis was involved in the cicatricial process in 3 patients. Patients with 3rd–4th degree of stenosis according to the Mayer-Cotton classification prevailed (Table 2).

Table 2. Characteristics of children with chronic cicatricial post-intubation stenosis of the larynx from Group 2

Localization	Mayer-Cotton Degree of Stenosis			Tracheostoma
	II	III	IV	
Glottic (n = 3)	1	2	0	3
Subglottic (n = 24)	2	14	10	24
Total	3	16	10	27

Interventions were performed using total intravenous anesthesia and muscle relaxation. We used an anterior neck approach with laryngofissure. The formation of a persistent laryngotracheostomy followed by multistage reconstruction in 18 patients or simultaneous reconstruction of the cartilaginous frame and larynx lumen using cartilaginous costal autografts in 9 cases was performed with an external approach.

In 5 cases anterior grafts were used, and in 4—posterior grafts (Fig. 2 and Fig. 3).

RESULTS AND DISCUSSION

Group 1. For stenosis of the vestibular part of the larynx (n=1), we performed laser excision of the scar tissue of the upper larynx with the formation of mucous microflaps, which made it possible to expand the lumen with a minimal wound surface; in this case, a stable functional result was achieved.

In the presence of cicatricial stenosis of the middle larynx (n=7), laser excision of the scar tissue was performed in the superpulse mode, with the maximum energy density, with an average laser power of 8

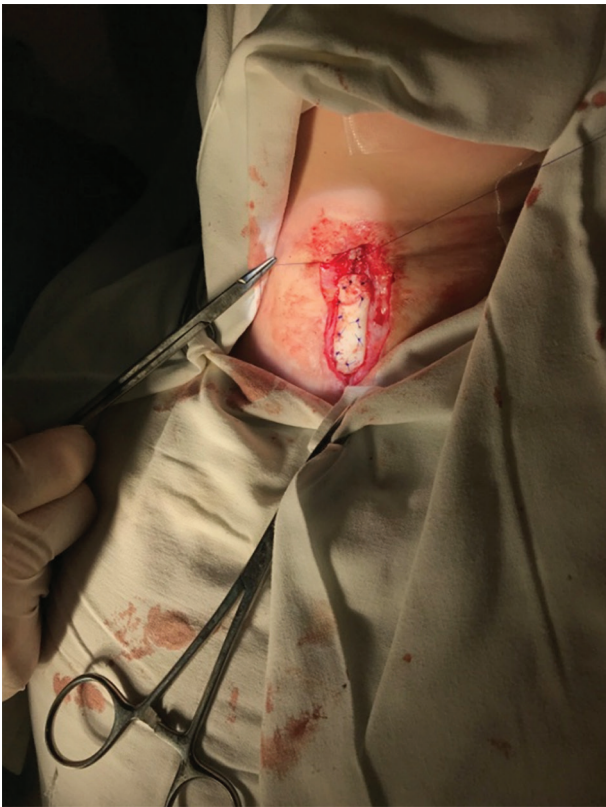

Fig. 2. Insertion of the anterior graft

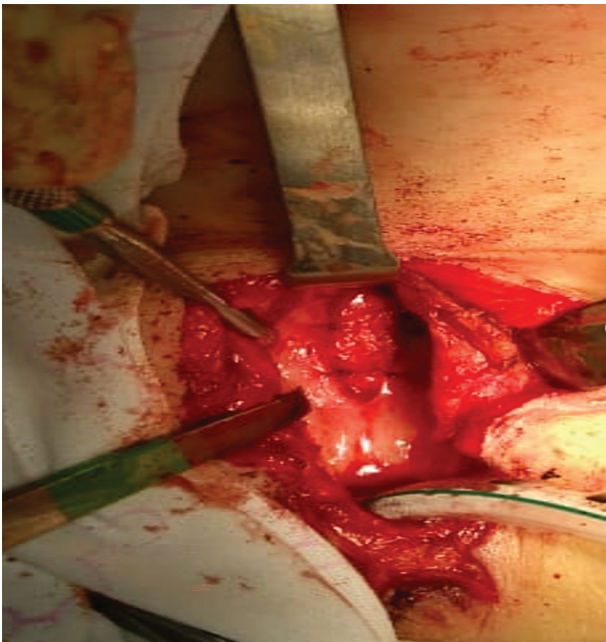


Fig. 3. Insertion of the posterior graft

W. In 2 patients, in connection with the involvement of the commissure in the pathological cicatricial pro-

cess, the formation and fixation of microflaps was carried out in order to separate the wound surfaces, which made it possible to achieve a stable functional effect. In 5 cases, after excision of the scar membrane in the area of the commissure, a keeled endoprosthesis was fixed, preventing the contact of wound surfaces, which was fixed with a Lichtenberg suture. The endoprosthesis was retained in the larynx for the period of formation and remodeling of scar tissue until complete epithelialization of the wound, which corresponded to a period of at least 21 days (Fig. 4). Pa-

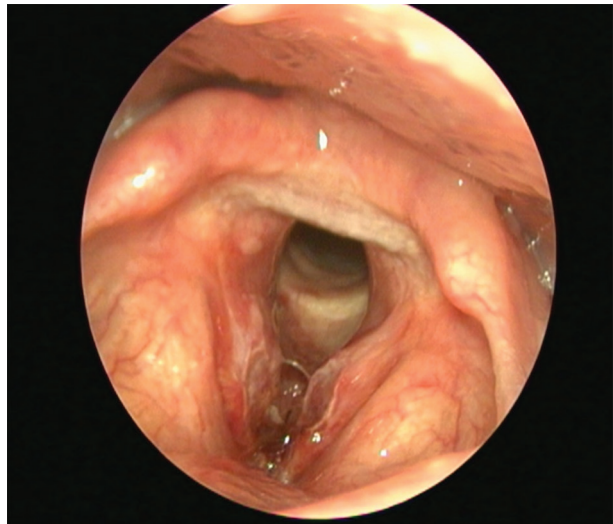


Fig. 4. Laryngoscopic picture when installing a keeled endoprosthesis in the area of the laryngeal commissure

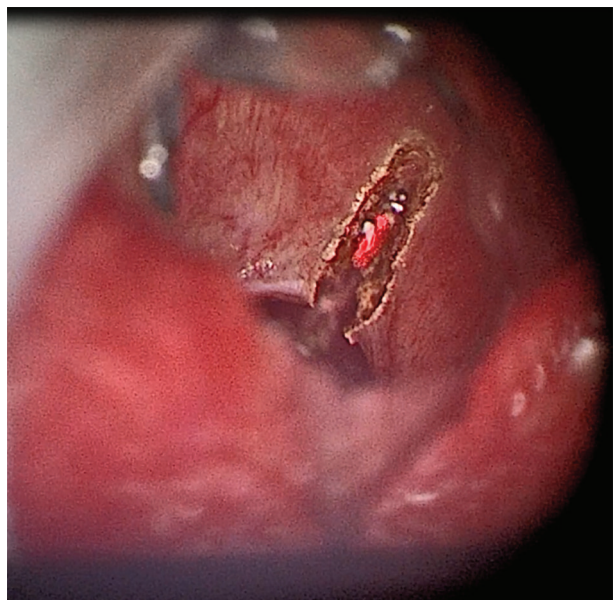


Fig. 5. The stage of dissection of the cicatricial narrowing of the laryngeal larynx with a CO2 laser

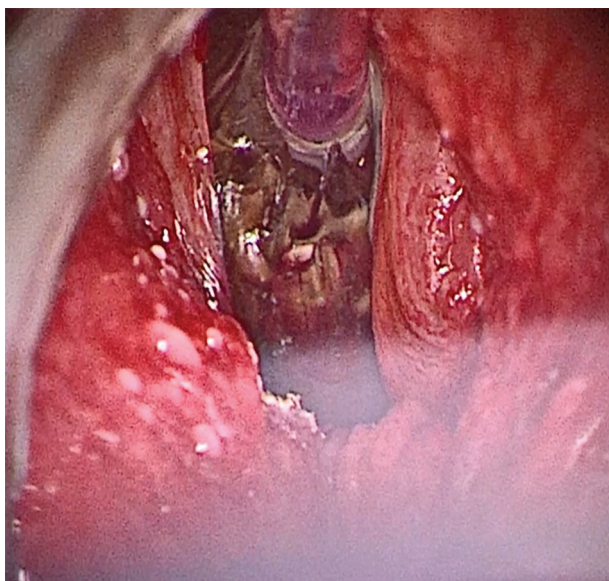


Fig. 6. Stage of balloon dilatation of cicatricial narrowing of the laryngeal lining

tients with laryngeal stenosis (n=12) underwent radial dissection of the scar tissue in the superpulse mode, with a maximum energy density, an average laser power of 8 W. After that, dilatation of this part of the larynx was performed (Fig. 5 and Fig. 6), using a balloon (Boston Scientific) with pressure of 12 atm.

Endoscopic control after 2 weeks revealed that 7 patients were prone to restenosis, which required repeating the same procedures. A follow-up examination after another 2 weeks showed signs of restenosis in 5 patients, which required further reconstruction of the cartilaginous frame of the larynx.

These unsatisfactory results of endolaryngeal surgery were associated with perichondritis in the region of the cricoid cartilage in 3 children, and extensive and massive scarring with preserved cartilaginous frame of the larynx in 2 patients.

Follow-up for a period from 6 months to 3 years showed the achievement of a stable functional result in 14 children from the first group. In one case after a year excision of the scar membrane of the middle part of the larynx was required, in 5 cases laryngoplasty with extralaryngeal access was performed.

Group 2. In all 27 patients we achieved a normal lumen of the larynx followed by decannulation by creating a stable frame of the larynx. In 18 cases, laryngotracheofissure was performed, followed by long-term stenting of the lumen of the larynx and

trachea (from 6 to 18 months). After the stent removal, the observation period was about 1 month after which, in case of stable lumen, the laryngotracheostomy was sutured. In 6 cases, it was additionally required to strengthen the larynx frame with costal cartilage. In 9 cases, laryngofissure with the formation of a persistent laryngotracheostomy followed by multistage reconstruction in 18 patients or simultaneous reconstruction of the cartilaginous framework and laryngeal lumen using cartilaginous costal autografts was performed using the extralaryngeal approach. In 5 cases, anterior grafts were used, in 4—posterior ones (Fig. 2 and Fig. 3). To stabilize the position of the grafts and form a sufficient lumen of the larynx, a silicone endoprosthesis was installed into the lumen of the larynx for 21 days. It was removed endolaryngeally.

Follow-up for a period from 8 months to 4 years showed the achievement of a stable functional result in all 9 children (Fig. 7 and Fig. 8). In one case after 6 months balloon laryngoplasty was required.

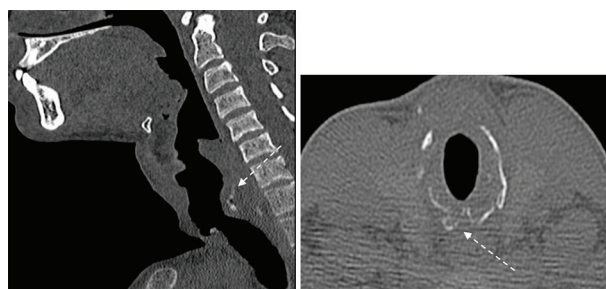


Fig. 7. Location of cartilage graft (CT picture after 1 year)

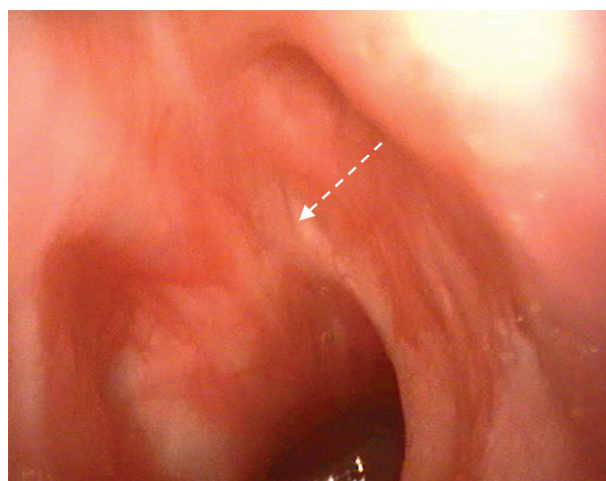


Fig. 8. Endoscopic view (the anterior graft is completely covered with epithelium after 6 months)

CONCLUSION

The use of a CO₂ laser in combination with balloon laryngoplasty in microsurgical treatment of chronic post-intubation stenosis of the larynx in children significantly expands the surgical capabilities due to high accuracy and low level of damage of surrounding tissues. This method allows the formation of minimal wound surfaces by submucosal excision of scar tissue and gives the possibility of covering the wound with mucosal microflaps. This technique significantly reduces the time of epithelialization in the intervention area. This is an important factor of restenosis prevention. In the surgical treatment of extended stenosis of the middle part of the larynx, especially in the area of the commissure, the creation of an extensive de-epithelialized wound surface is inevitable, which creates the precondition for repeated scar formation, especially in the area of possible contact of the wound surfaces. In our observations, such an effect was avoided by using endoprostheses for a period of 21 days. The subglottic lesion in children with chronic cicatricial post-intubation stenosis is the most common localization. This zone is prone to restenosis, even in the absence of data for damage to the cartilaginous laryngeal frame.

In case of ineffectiveness of endoscopic methods and in case of a lesion of the laryngeal skeleton, external access laryngotracheoplasty is preferable. The use of cartilage rib grafts is a particularly promising area in such laryngosurgery. It can significantly reduce the number of stages, the duration of surgical treatment, and subsequent rehabilitation. In addition, the use of autotissue grafts excludes the development of a number of complications such as rejection, immunological response, infection, lysis, which we did not observe in the group of our patients.

REFERENCES

1. Fiz I, Monnier P, Koelmel JC, Di Dio D, Torre M, Fiz F, et al. Implementation of the European Laryngological Society classification for pediatric benign laryngotracheal stenosis: a multicentric study. *Eur Arch Otorhinolaryngol.* 2019;276(3):85-792. doi: 10.1007/s00405-019-05353-4.
2. Nazarochkin YV, Garashtenko TI, Boykova NE, Stroykova MA, Avedisyan VE. Complications of tracheal intubation and tracheostomy after prolonged mechanical ventilation in children. *Pract Pediat.* 2015;10(5):68-72. (in Russian).
3. Chia AZH, Ng ZM, Pang YX, Ang AHC, Chow CCT, Teoh OH, et al. Epidemiology of Pediatric Tracheostomy and Risk Factors for Poor Outcomes: An 11-Year Single-Center Experience. *Otolaryngol Head Neck Surg.* 2020;162(1):121-8. doi: 10.1177/0194599819887096.
4. Schroeder JW Jr, Greene RM, Holinger LD. Primary closure of persistent tracheocutaneous fistula in pediatric patients. *J Pediatr Surg.* 2008;43(10):1786-90. doi: 10.1016/j.jpedsurg.2008.01.010.
5. Watters KF. Tracheostomy in Infants and Children. *Respir Care.* 2017;62(6):799-825. doi: 10.4187/respcare.05366.
6. Sandu K, Monnier P. Cricotracheal resection. *Otolaryngol Clin North Am.* 2008;41(5):981-98, x. doi: 10.1016/j.otc.2008.04.012.
7. Pavlov PV, Zaharova ML, Kornievskii LA. Modern aspects of laryngotracheal reconstruction in children. *Pediatrics.* 2017;8(5):251. (in Russian).
8. Alshammari J, Arafat A, Halawani M. Laser-assisted endoscopic cricotracheal stenosis resection (CTSR) in paediatric congenital cartilaginous subglottic stenosis. *Int J Otolaryngol.* 2020;2020:9528249. doi: 10.1155/2020/9528249.
9. Monnier P, George M, Monod ML, Lang F. The role of the CO₂ laser in the management of laryngotracheal stenosis: a survey of 100 cases. *Eur Arch Otorhinolaryngol.* 2005;262(8):602-8. doi: 10.1007/s00405-005-0948-8.
10. Arroyo HH, Neri L, Fussuma CY, Imamura R. Diode Laser for Laryngeal Surgery: a Systematic Review. *Int Arch Otorhinolaryngol.* 2016;20(2):172-9. doi: 10.1055/s-0036-1579741.
11. Haykal S, Salna M, Waddell TK, Hofer SO. Advances in tracheal reconstruction. *Plast Reconstr Surg Glob Open.* 2014;2(7):e178. doi: 10.1097/GOX.0000000000000097.
12. Karasu MF, Gundogdu R, Cagli S, Aydin M, Arli T, Aydemir S, et al. Comparison of effects on voice of diode laser and cold knife microlaryngology techniques for vocal fold polyps. *J Voice.* 2014;28(3):387-92. doi: 10.1016/j.jvoice.2013.10.017.
13. Steiner W., Fagan J. Transoral laser microsurgery (TLM) of cancer & other pathology of the upper aerodigestive tract. *The open access atlas of otolaryngology, head & neck operative surgery;* 2017. p. 30.

14. Xu W, Han D, Hou L, Zhang L, Yu Z, Huang Z. Voice function following CO2 laser microsurgery for precancerous and early-stage glottic carcinoma. *Acta Otolaryngol.* 2007;127(6):637-41. doi: 10.1080/00016480600987776.
15. Yan Y, Olszewski AE, Hoffman MR, Zhuang P, Ford CN, Dailey SH, Jiang JJ. Use of lasers in laryngeal surgery. *J Voice.* 2010 Jan;24(1):102-9. doi: 10.1016/j.jvoice.2008.09.006.
16. Doody J, Alkhateeb A, Balakrishnan K, Bedwell J, Carter J, Choi SS, et al. International Pediatric Otolaryngology Group (IPOG) consensus recommendations: Management of suprastomal collapse in the pediatric population. *Int J Pediatr Otorhinolaryngol.* 2020;139:110427. doi: 10.1016/j.ijporl.2020.110427.