

ECTOPIC PREGNANCY AFTER ASSISTED REPRODUCTIVE TECHNOLOGY: A RETROSPECTIVE STUDY

Kovachev E.^{1,2}, S. Ivanov¹, A. Abbud¹, A. Tsonev¹

¹*Department of Obstetrics and Gynecology, Medical University - Varna*

²*Medical Centre of Assisted Reproduction "Varna" LTD, Varna*

Reviewed by: prof. St. Ivanov

ABSTRACT

In this study from 2006 to 2010, 1628 IVF-ET cycles were performed in our unit. Long protocol with GnRH agonist plus recombinant FSH, short protocol with GnRH antagonist, short protocol with microdoses of GnRH agonist (flare up), natural modified cycle with GnRH antagonist and hCG were applied. The serum level of the β -hCG was measured 12 days after embryo transfer (ET). When positive, the β -hCG level was determined every 4 days until the ultrasound examination 22 days after the ET. From 1628 IVF - ET cycles, we had 10 tubal pregnancies (0,61%) and one heterotopic pregnancy (HP). Salpingectomy was performed in all patients, 7 had laparoscopy, and 3 underwent emergent laparotomy due to hemorrhagic shock. Regarding the HP patient, an ultrasound scan confirmed a viable intrauterine 8-weeks gestation and an ectopic pregnancy (EP) in the left tube with fetal heartbeat corresponding to gestational age of 7-8 weeks. Laparoscopy with left salpingectomy was performed the following day. The intrauterine pregnancy proceeded uneventfully. The patient delivered by elective Cesarean section at 39 weeks of gestation due to breech presentation. Patients undergoing IVF-ET must be informed of the risk of EP and the possibility of HP should not be ignored.

Key words: IVF, ectopic pregnancy, heterotopic pregnancy

INTRODUCTION

The incidence of ectopic pregnancy (EP) varies between 0,3%-1,4% of all pregnancies. Nearly 95 percent of EP are implanted in the various segments of the fallopian tubes. Of these, most are ampullary implantations. EP is considered to be a true public health problem since it is still a major cause of maternal morbidity and mortality, accounting for 9%-13% of all pregnancy - related deaths in the United States and representing the fourth most frequent cause of maternal death in the United Kingdom. The first in vitro fertilization (IVF) pregnancy reported was an EP in 1976 (15). After one ectopic pregnancy, the risk of recurrence is between 10-20% (8). The rate of extrauterine pregnancies is higher after IVF and may occur in 4-5%.

Heterotopic pregnancy (HP) is the co-existence of intra- and extrauterine gestations and occurs in natural conception in 1:30000 pregnancies. Worldwide, the incidence has increased to 1:100 after IVF and multiple embryo transfer (ET).

Factors predisposing for EP are tubal damage after pelvic inflammatory disease, endometriosis or tubal corrective surgery,

previous EP, tubal sterilization, progesterone intrauterine device and exposure to diethylstilbestrol in utero.

Peritubal adhesions subsequent to salpingitis, postabortal or puerperal infection, appendicitis may increase the risk for EP. There are some risk factors for ectopic implantation in assisted reproductive technology (ART) including reduction in tubal contractility as a result of high progesterone levels from multiple corpus lutea, ovarian hypervascularity after hyperstimulation and egg retrieval, excessive endometrial cavity distention with media during embryo transfer, deep fundal ET, high number of the transferred embryos, uterine malformations (13). It has been hypothesized that, even correctly transferred embryos can migrate into fallopian tubes, due to retrograde action of uterine secretions and/or uterine contractions (16). The transfer volume of culture media containing embryos may play a role in embryonic migration into the fallopian tubes. While most clinicians contend that more than 80 μ l of media are needed for the embryo to reach the fallopian tube.

MATERIAL AND METHODS

During the years 2006 through 2010, 1628 IVF-ET cycles were performed in our unit. All patients underwent pre-

Address for correspondence:

E. Kovachev, SBAGAL - Varna, Dept. of Obstetrics and Gynecology; Medical Centre of Assisted Reproduction "Varna" Ltd, 150, Tsar Osvoboditel Blvd, 9000 Varna - Bulgaria
e-mail: kovachev_md@abv.bg

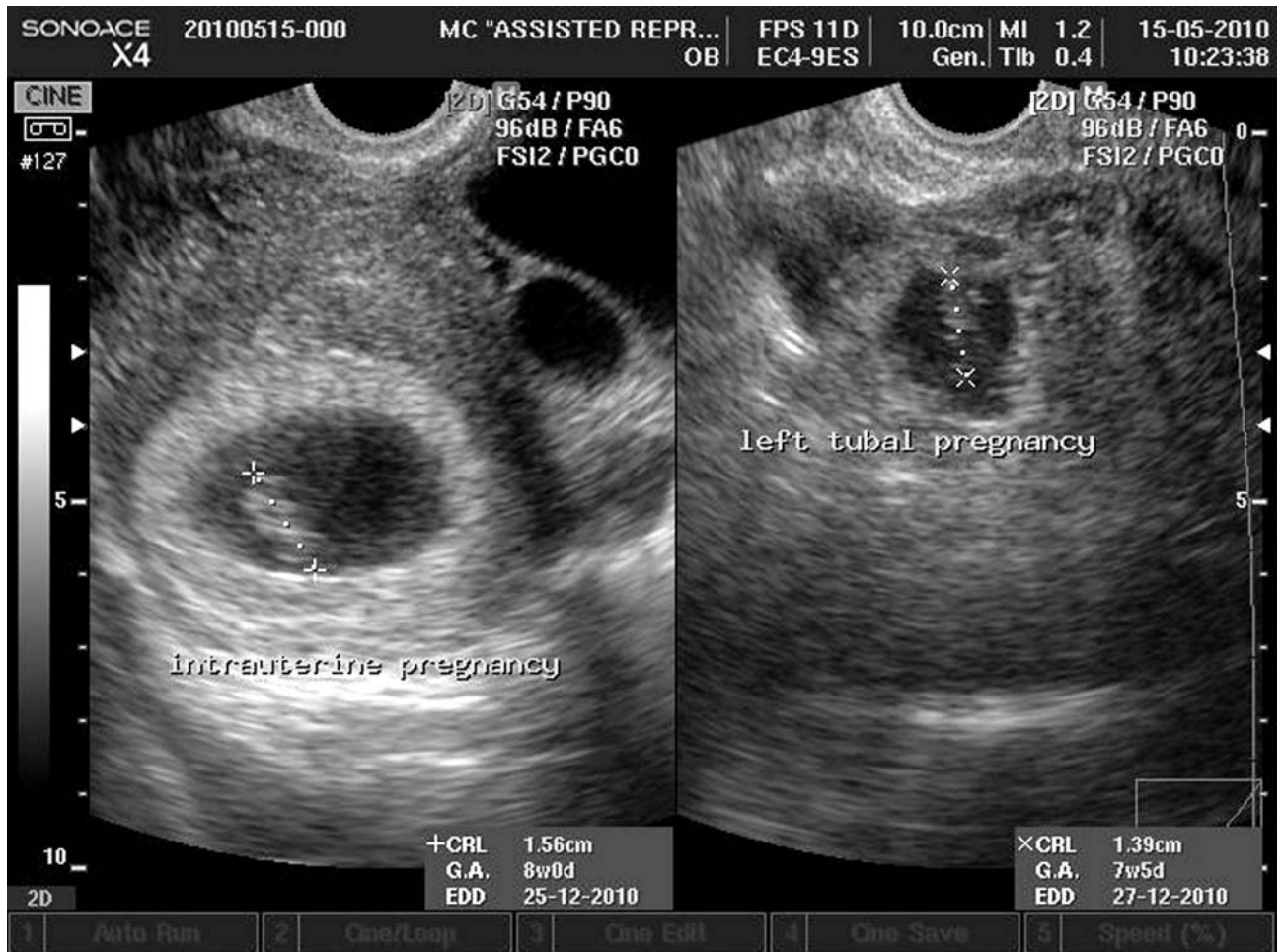

Figure 1. Heterotopic pregnancy (our case).

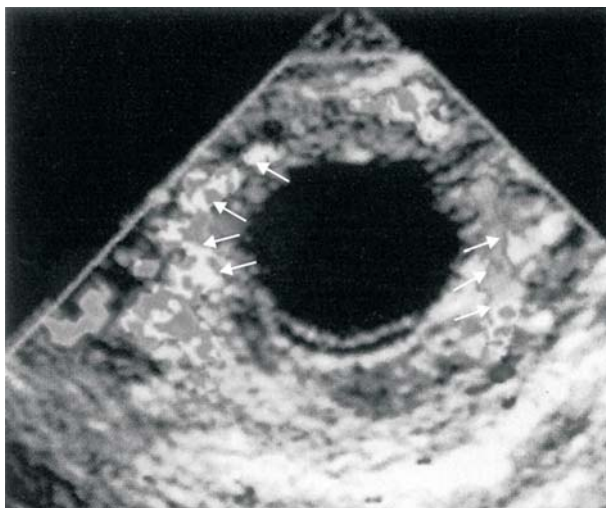


Figure 3. Color Doppler transvaginal sonogram of an ectopic pregnancy. The “ring of fire” reflects placental blood flow around the periphery of the pregnancy.

treatment with oral contraceptive pills (OCPs) for 21 days. COH was performed using both classical long protocol with GnRH agonist (Triptorelin, Decapeptyl; Ferring, Ger-

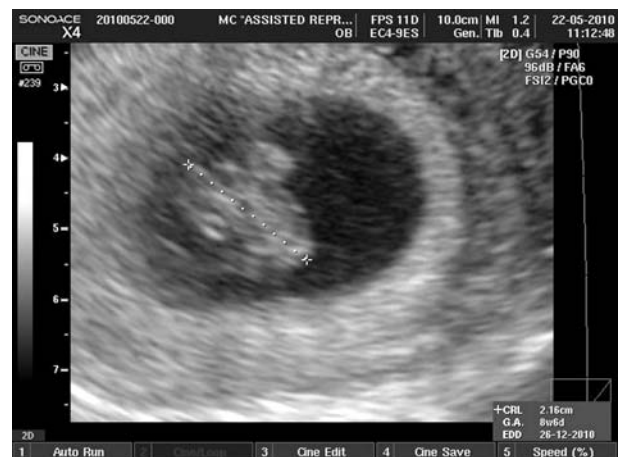

Figure 2. Intrauterine pregnancy with fetal heartbeat one week after a laparoscopic salpingectomy (our case).

many) plus recombinant FSH (Follitropin alfa, Gonaf-F; Merck-Serono, United Kingdom) and short protocol with GnRH antagonist (Cetrorelix, Cetrotide; Merck-Serono, United Kingdom).

The starting dose depended on the patient's age, body mass index or previous ovarian response. GnRH antagonist was ap-

plied when the leading follicle was ≥ 14 mm. The serial ultrasound and serum E2 measurements monitored the follicular growth. Oocyte retrieval was performed 35-36 hours following hCG administration. ET was realized 48-72 hr after oocyte retrieval. Embryos were suspended in 30 μ l of culture media (BlastAssist®, Origio; Denmark) in a Wallace catheter (Smiths Medical International, United Kingdom) and transabdominal ultrasound guidance was used to place the embryos 1-2 cm from the fundus without traumatizing and inducing uterine contractions. Two embryos were transferred and the remaining embryos were cryopreserved. Luteal support was performed by daily micronized P vaginally (Utrogestan® 200mg, 3x/day), starting the day after the oocyte retrieval and continuing until the day of the pregnancy test. The serum level of the β -hCG was measured 12 days after ET. When positive, the β -hCG level was determined every 4 days thereafter or until an intrauterine gestational sac was demonstrated by ultrasonography. The first transvaginal scan performed 22 days after ET, demonstrated a gestational sac in the uterine cavity. Identification of an extrauterine gestational sac containing a yolk sac (with or without an embryo) confirmed the diagnosis. Suggestive findings included solid adnexal or tubal mass (including the tubal-ring sign, representing a tubal gestational sac), and echogenic cul-de-sac fluid. In some cases we performed also a color Doppler which showed a peritrophoblastic flow (figure 3).

RESULTS

From 1628 IVF - ET cycles we had 10 tubal pregnancies (0,61%) and one HP. The location of 8 ectopic pregnancies was ampullar and 2 were in isthmus portion. Salpingectomy was performed in all patients, seven of them were done by laparoscopy, and three underwent emergent laparotomy due to hemorrhagic shock.

The abdomen was opened through a Pfannenstiel incision. Histopathologic examination confirmed the diagnosis of EP in all cases. The patients did well postoperatively and were discharged after 3-5 days. Serum β -hCG level was followed up and the values showed a progressive decline confirming the efficiency of the treatment.

The patient with HP, was referred to the hospital with a mild lower abdominal pain. An ultrasound scan confirmed a viable intrauterine gestation (eight weeks gestation) and an EP in the left tube with a fetal heartbeat and a crown-rump length measuring 1,39 cm that corresponded to a gestational age of 7 weeks and 5 days (figure 1). Laparoscopy with left salpingectomy was performed the following day. The intrauterine pregnancy proceeded uneventfully (figure 2). Due to breech presentation, the patient delivered a healthy 2850 g male infant by elective Cesarean section at 39 weeks of gestation.

DISCUSSION

The use of ovarian hyperstimulation drugs, multiple ET, and the techniques of ET, along with previous tubal damage predisposes patients to develop EP and HP (10). The use of a

tenaculum might arouse uterine contractions especially in the subendometrial myometrium and should be avoided by using a gentle, atraumatic transfer technique (5).

Ectopic pregnancy is increased in patients with hydrosalpinx and has a deleterious effect on the implantation of the transferred embryos, for a number of reasons (7). The tubes are often inflamed which may result in the release of cytokines into the tubal fluid due to inhibited embryo implantation and may cause a mechanical flushing of embryos transcervically (14). It has been suggested that the treatment of patients with hydrosalpinx should be unilateral or bilateral salpingectomy prior to IVF. In fact, many patients with interstitial or cornual pregnancy after IVF-ET have undergone bilateral salpingectomy and the absence of a Fallopian tube does not remove the risk of interstitial or cornual pregnancy (11). Bilateral salpingectomy cannot avoid subsequent heterotopic pregnancy completely (2, 9). A number of investigators have described discriminatory β -hCG levels (1500 mIU/mL) above which failure to visualize a uterine pregnancy indicates with high reliability that the pregnancy either is not alive or is ectopic (3). Demonstration of a live embryo within a gestational sac outside the uterus is the gold standard for the sonographic diagnosis of ectopic pregnancy (4). The presence of ovarian hyperstimulation syndrome (OHSS) during ART might mask the EP signs in HP cases thus preventing a definitive diagnosis prior to surgery (12). Over half of all HP are recognized during emergency surgeries following tubal rupture (2). Treatment of HP is complicated because of the co-existing intrauterine pregnancy and should be the least invasive as possible in order to achieve a good outcome for the intrauterine pregnancy. Nevertheless, the laparoscopic approach (salpingostomy or salpingectomy) is the first choice especially in the early diagnosed cases (6). Laparotomy is generally performed in hemodynamically unstable cases with a ruptured EP (3). Serum β -hCG levels and VEGF concentration increase with deeper trophoblast penetration into the tubal wall and it is possible to be used as a good discriminator of the histological stages of invasion (1). Their levels might be useful in clinical practice and could help to decide whether or not to remove fallopian tubes affected by EP (conservative or radical treatment).

CONCLUSION

A high index of suspicion and early intervention, are mandatory to salvage the viable intrauterine pregnancy and prevent maternal mortality. Symptoms and signs of ectopic pregnancy are often subtle or even absent.

Ectopic pregnancy in unpredictable locations is very likely to occur after IVF-ET. Therefore it is compulsory to perform an early β -hCG monitoring and transvaginal ultrasonography even in women without known risk factor in order to discover possible ectopic pregnancy at an early stage. In high-risk patients for EP and HP it is advisory a single ET to take place and multiple pregnancy to be avoided.

Our study shows that EP after IVF-ET is considerably lower than it is described in the foreign literature. Possible explanation is that a laparoscopic salpingectomy is performed to the majority of patients after diagnosing hydrosalpinx and receiving their informed agreement. It decreases the risk of tubal pregnancy, and increases the percent of clinical pregnancy. For the past 5 years other localizations of EP have not been determined. When ultrasonography reveals an intrauterine pregnancy the possibility of HP should not be rejected. Women undergoing IVF-ET must be informed of the risk of ectopic and heterotopic pregnancy.

REFERENCES

1. Cabar FR, Pereira PP, Schultz R, Rossana F, Zugaib M. Vascular endothelial growth factor and β -human chorionic gonadotropin are associated with trophoblastic invasion into the tubal wall in ectopic pregnancy. *Fertil Steril* 2010; **94**: 1595-1600.
2. Chang Y, Lee IN, Yang CH, Hsu SC, Tsai EM. An unexpected quadruplet heterotopic pregnancy after bilateral salpingectomy and replacement of 3 embryos. *Fertil Steril* 2002; **80**: 218-220.
3. Cunningham G, Leveno K, Bloom S, Hauth J, Rouse D, Spong C. Williams Obstetrics, 23 rd Edition; McGraw-Hill Companies; 2010; 238-256.
4. Fousseyni MD, Mamadou ST. Sonographic detection of unruptured dichorionic unilateral live twin ectopic pregnancy. *Journal of Diagnostic Medical Sonography*. 2007; **23**: 372-4.
5. Gardner DK, Weissman A, Howles CM, Shoham Z. Textbook of assisted reproductive technologies. 3 rd ed. UK: *Informa Health Care*; 2009; 790-791.
6. George M, Nadarajah S, Ong CL. Unilateral twin ectopic pregnancy. *JHK Coll Radiol* 2010; **12**:186-9.
7. Jiao Z, Zhuang G, Zhou C. Ectopic pregnancy after in vitro fertilization and embryo transfer: clinical analysis of 17 cases. *Zhonghua Fu Chan Ke Za Zhi*. 2001; **36**(7): 411-413.
8. Kissler S, Wiegratz I, Kohl J, Rody A, Gaetje R, Kaufmann M. Repeated ectopic pregnancy after ICSI therapy and embryo transfer - A case report and literature review. *J. Reproduktionsmed. Endokrinol* 2006; **3** (6), 387-389.
9. Knopman JM, Talebian S, Keegan DA, Grifo JA. Heterotopic abdominal pregnancy following two-blastocyst embryo transfer. *Fertil Steril* 2007; **88**(5): 1437.
10. Lou X, Lim CE, Huang C, Wu J, Wong WS, Cheng NC. Heterotopic pregnancy following in vitro fertilization and embryo transfer: 12 cases report. *Arch Gynecol Obstet*. 2009; **280**(2): 325-329.
11. Moir D, McMahon K. Cornual ectopics - two case studies. *ASUM Ultrasound Buletin* 2004 August **7**:23-25.
12. Moosburger D, Tews G. Severe ovarian hyperstimulation syndrome and combined intrauterine and tubal pregnancy after in-vitro fertilization and embryo transfer. *Hum Reprod* 1996; **11**(1): 68-69.
13. Oki T, Douchi T, Nakamura S, Maruta K, Ijuin H, Nagata Y. A woman with three ectopic pregnancies after in-vitro fertilization and embryo transfer. *Hum Reprod* 1998;**13**: 468-470.
14. Speroff L, Fritz MA. Clinical gynecologic endocrinology and infertility. 7 th ed. Philadelphia: Lipincott Williams & Wilkins; 2005; 1278: 1294.
15. Steptoe PC, Edwards RG. Reimplantation of human embryo with subsequent tubal pregnancy. *Lancet* 1976; **24**:880-2.
16. Strandell A, Thorburn J, Hamberger L. Risk factors for ectopic pregnancy in assisted reproduction. *Fertil Steril* 1999; **71**(2): 282-286.