

## POSTOPERATIVE CARE AND MEASUREMENT AFTER SEPTO- AND RHINOPLASTY

Iliev G.

*Department of Otorhinolaryngology, University Hospital "St. Marina", Varna*

**Reviewed by: assoc. prof. Pl. Nedev**

### ABSTRACT

**INTRODUCTION:** Postoperative care starts with the application of a bed rest, antihypertensive therapy, steroids and antibiotics prophylactic, dressing, nasal packing, transmucoseptal sutures and controlling postoperative result. **MATERIAL AND METHODS:** We report our experience with postoperative care and measurement after septo- and rhino-plasty. We review the free access literature about the experience of other clinics in these problems and compared the results. **REVIEW:** In our review we present our postoperative care and those described by other authors. **DISCUSSION:** All postoperative care aims at preventing possible complications and shortening recovery. Most of them have been adopted as standard postoperative treatment and supervision. Topic of our discussion are the differences and similarities in their implementation compared to our practice. **CONCLUSION:** The postoperative care is more effective when we are aware of their strengths and weaknesses and we combine them individually for each patient.

**Key words:** postoperative care, nasal dressing, nasal packing, transmucoseptal suturing, splints

### INTRODUCTION

Postoperative care starts with the application of a bed rest, antihypertensive therapy, which is best begun preoperatively, and controlling undue and nausea. Steroids and antibiotics are given prophylactically to prevent infection and significant edema. It is important to communicate to the patient that a certain amount of edema is preferable and sets up a natural healing process. The edema process washes the area clean and allows for the tissues to begin a healthy healing phase. A limited activity level for a period of one to two weeks and a diet high in protein, with vitamins, and low in salt will help ensure a good result. Communication with the patient is essential during this period of time, and any unusual fever, pain, purulent discharge; bleeding or instability of the dressing should be reported immediately. Long-term care of the patient centers around minimizing direct trauma to the nose and careful observation by the surgeon for a period of up to two years (13). In order to become a good nose surgeon, follow-up of at least one year (postoperatively) is necessary to follow the dynamics of the healing process, thereafter at five to ten years (9).

### MATERIAL AND METHODS

After receiving approval from the Ethic committee of our institution, we retrospectively evaluated postoperative care

#### Address for correspondence:

G. Iliev, Dept. of Otorhinolaryngology, University Hospital "St. Marina", Varna  
e-mail: apetko59@abv.bg

and measurement after septo- and rhinoplasty in 386 patients between 2009 and 2011. We report our experience with postoperative care and measurement after septo- and rhino-plasty. We review the free access literature about the experience of other clinics in these problems and compared the results. We found 17 articles with comparative topics and we deduced their experience in our study.

### REVIEW

#### *Dressing*

Postoperative care after packing/suturing/splint continues with the application of an adequate internal and external nose dressing. In our clinic we practice external dressing after rhinoplasty for one week. Before the patch we first clean the skin with salicylic alcohol and do some well-fitting bandage layer of sliced "Hypafix" strips, then put a metal splint and continue with "Hypafix" bands. Twenty-four hours after the surgery we cut the part of the bandage that covers the nose and remove the nasal tampon.

Some authors report their experience in the literature about the placement of a bandage after rhinoplasty. Before applying the external dressing, operative edema, if any, is reduced by massage of the nasal covering. Thereafter, the skin of the nose is rubbed with Tinctura Benzoin or Mastisol followed by the application of a piece of gel foam, after which overlapping strips of paper-tape are applied, right across the bridge of the nose, including the supra-tip area. A sling of paper-tape is then applied, not extending below the nostril apexes, to enclose the lobule (9).

As a splint, various materials, such as aluminum, plastic or plaster of Paris, can be used. The splint only covers the bridge of the nose. The dressing procedure is finished by a "moustache dressing" to catch any nasal discharge. External nose dressings are generally removed after one week (9).

### *Nasal packing and septal suturing*

We used in a light compact loose porous gauze tamponade for the first 24 hours. In the literature, some findings confirm that nasal packing after septoplasty is not only unnecessary, but it is actually a source of patient discomfort and other signs and symptoms (4). Others practise a simple method of fabricating nasal packing armed with a ventilation tube (16), still others - a new intranasal dressing after septorhinoplasty with Polyethylene oxide gel (17).

We have developed a simple, inexpensive method for performing transseptal suturing that is easy to use in the nasal cavity. We used a nasal splint in the majority of our patients. For splint we used X-ray plates or medical silicone. Some authors have adopted the transseptal sutures as a standard. Most scientific papers deal with their efficiency without or in combination with nasal packing, splints, etc. or are considered types of sutures. Some authors have used nasal splint in part of the analyzed groups in their scientific research (9,3,11).

### *Corticosteroids and antibiotics*

We administer prophylaxis with antibiotics to most of our patients, for 5 days after septo- or rhinoplasty. We use Amoxicillin & Clavulanic acid film tab. 1g twice a day. We also prescribe Methylprednisolone or Betamethasone postoperatively - twice - one hour after surgery and on the 24<sup>th</sup> hour.

There are different opinions in the literature for and against antibiotic prophylaxis (7). Some of them recommend the use of prophylactic antibiotics rather than empirical postoperative antibiotics for patients undergoing complex septorhinoplasty (2). The corticosteroids are commonly used as a postoperative care, differences are only in the manner of the prescription (8,15,10).

## **DISCUSION**

All postoperative care aims at preventing possible complications and shortening recovery. Most of them have been adopted as standard postoperative treatment and supervision. Topic of our discussion are the differences and similarities in their implementation compared to our practice.

In terms of bandages after rhinoplasty there are no significant differences between our practice and those of the other authors. The placement of immediate postoperative dressings should really be considered an extension of the actual surgical procedure, and although it probably does not impact the final result as much as the actual surgical manipulation of tissues, it certainly influences the outcome to quite a considerable degree. The dressings actually help the healing process as a continuation of the surgery. During surgery, the tissues are changed and then placed in certain specific areas. These tissues will begin to heal so that scar tissue or potential scar

tissue will eventually mold and blend the tissues together and sometimes contract, which will allow the nose to achieve its final form. Dressings play a very important role in allowing the healing tissues to accomplish this by stabilizing them in a preset way that will enhance healing. It is similar to setting a fractured leg, in that you want the structural elements of the reconstruction to stay where they should be until all the areas have initially healed (13). The goal of the external nose dressing is as follows (9):

- to fix the skin on the under-layer, thereby reducing dead space;
- to prevent hematomas and swelling;
- to prevent displacement by outside trauma;
- to prevent widening of the lateral walls by intranasal edema.

Only in specific operative techniques, such as wedge excisions with pushdown of the bony pyramid, does the external nose dressing also aim at fixing and shaping the bony pyramid. Inadequate fractured nasal bones cannot be fixed permanently by the external nose dressing. The external nose dressing consists of three layers, e.g. hypoallergenic paper-tape, adhesive cloth-tape and splint (9).

In terms of nasal packing and septal suturing there are different opinions as to which technique or combination of techniques is a much better and gives better results.

The use of nasal packing following septoplasty has been proposed to serve multiple purposes. One of the most common reasons for the use of packing is to prevent postoperative complications such as bleeding and formation of either synechiae or a septal hematoma. Stabilization of the remaining cartilage to prevent postoperative deviation is another reason that packing may be used (6).

The ideal intranasal dressing should conform to the irregularities of the nasal cavity and resist adherence to the wounds of the nasal lining so it can be easily removed. It should be nonirritating, antiseptic and economical. Polyethylene oxide gel appears superior to the previously described dressings, primarily because of comfort for the patient at removal (17).

Some have found that the patients who underwent packing experienced significantly more postoperative pain, headache, epiphora, dysphagia and sleep disturbance on the night of surgery (9) as well as cardiovascular changes, continued bleeding, nasal injury, hypoxia, foreign body reaction or infection (12). Oral and nasal examinations 7 days postoperatively revealed no significant difference between the two groups (who had or had not undergone nasal packing following septoplasty) in the incidence of bleeding, septal hematoma, adhesion formation, and local infection. Finally, the packing group reported a moderate to high level of pain during removal of the packing. Their findings confirm that nasal packing after septoplasty is not only unnecessary, but is actually a source of patient discomfort and other signs and symptoms (4).

Some researchers have developed an easy method to fabricate nasal packing materials with airway maintenance by means of Merocel and an elastic suction catheter (17).

With limited evidence to suggest a beneficial effect and a potential for deleterious side-effects, the routine use of postoperative packing following septoplasty should be questioned (6).

Septal suturing preventing subperichondral hematomas further reduces the necessity of lengthy packing (9). A similar technique of septal suturing after nasal septoplasty without nasal packing was used in consecutive surgical procedures and reviewed retrospectively. Complications such as postoperative episodes of bleeding, infections, septal haematomas, septal perforations or synechia were not noted. Patients reported almost no discomfort. Moreover, the septal surgery procedure could be carried out on a daily surgery basis. Based on these observations the septal suturing technique is a valid alternative to intranasal packing following septal surgery (12).

The authors found no significant statistical differences between the two groups (using intranasal septal splints and antibiotic meshes at the end of the operation) and non-packing (using four separate trans-septum through and through horizontal mattress sutures without any mesh or intranasal splint) in the parameters studied (postoperative bleeding, hematoma, perforation and synechia), but significantly higher pain levels were noted in the patients in the packing group. The final results confirmed that patients who underwent septoplasty, intranasal packing and septal splint insertion did not benefit more than those who had trans-septum through and through suturing (3).

Nasal packing did not significantly influence the mucociliary clearance in the postoperative healing phase. No significant differences were found between the groups (Group 1: fingerstall packs filled with gauze and smeared with vaseline; Group 2: silicon septal splint packs; Group 3: haemostatic septal sutures) regarding mucociliary clearance before and after surgery. Patients with septal deviation

had a prolonged mucociliary transit time as compared with postoperative patients (11).

In our practice we use a combination of all of types of postoperative care. In our experience we use singular or permanent transmucoseptal sutures (fig. 1). We use postoperative splinting of the septum for temporary support (fig. 2). We remove the splints on 7<sup>th</sup> days postoperatively. For easier removal of the splint and helps prevent drying and crust in nasal cavity, we prescribed nasal sprays wash for 10/15 days after surgery. Light (if any) bilateral packing is enough

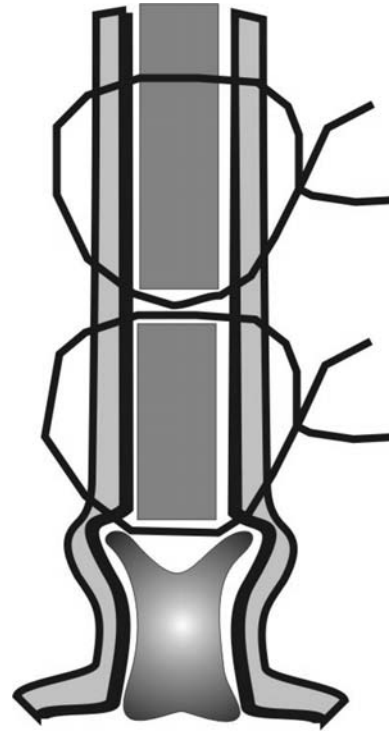


Fig.1. Transmucoseptal sutures

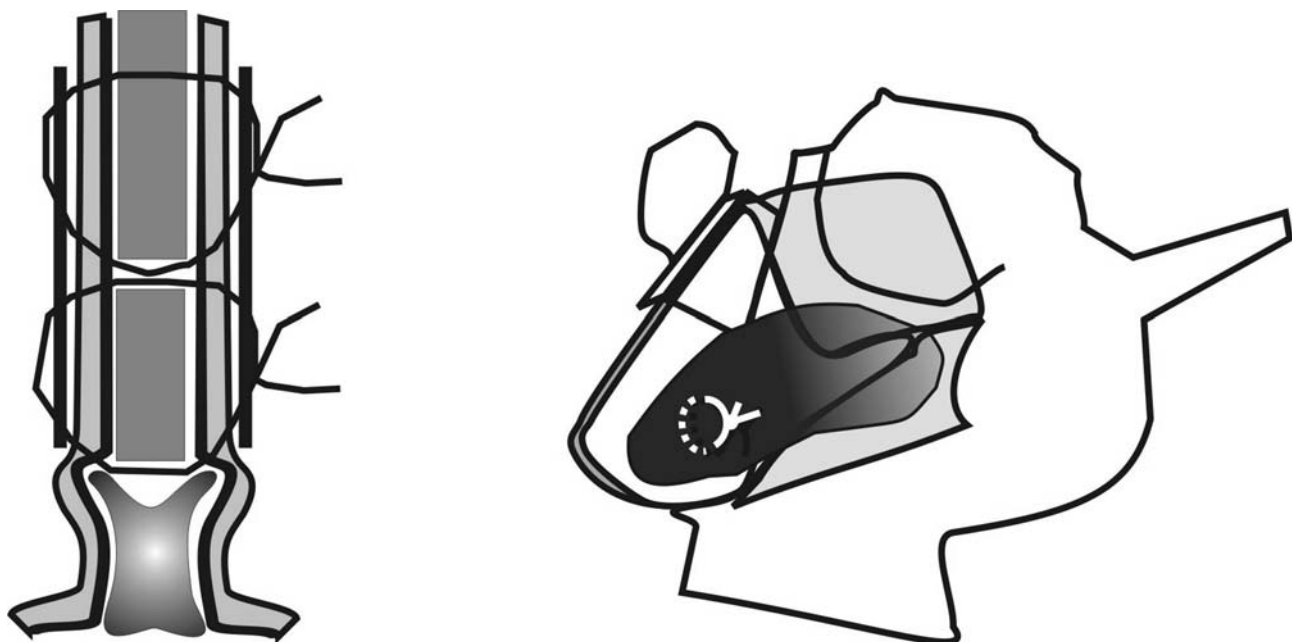

Fig.2. Splints fixing



for collecting the first bloody nasal discharge. This is removed 12 hours postoperatively. Thus we use only the advantages of each method.

Although some studies about the effects of steroids on surgical trauma in closed or combined (closed and open together) rhinoplasty have been reported in the literature, more information is needed in order to enlighten rhinoplastic surgeons. The anti-inflammatory activity of steroids administered in high doses prevents and decreases periorbital ecchymosis and oedema in patients who underwent open rhinoplasty with osteotomies by the same surgeon (8).

Clinically and statistically significant differences were observed in the decrease of both ecchymosis and oedema, between the placebo and high dose methylprednisolone groups, which is effective in preventing and decreasing both the ecchymosis and oedema in open rhinoplasty with osteotomies (8).

With single-dose Dexamethasone, periorbital edema can significantly be reduced on the first 2 postoperative days, and upper eyelid ecchymosis can significantly be decreased only on the first postoperative day. However, reoperative steroid administration has no influence on ecchymosis of the lower eyelid. Authors conclude that single-dose Dexamethasone 10 mg can be used safely to reduce periorbital edema and ecchymosis in rhinoplasty patients (15).

The best bet for decreasing postoperative edema and ecchymosis is triple-dose steroid application, when the first dose is given before osteotomy (10).

We stick to the double application of Methylprednisolone or Betamethasone on the first and second postoperative day.

Superficial pustulae of the skin caused by covering plasters usually disappear quickly after the removal of the dressing. The recovery can be speeded up by antibiotics and corticosteroid creams (9).

Prophylactic antimicrobial therapy during nasal surgery is common among surgeons worldwide, although the effectiveness of this practice is controversial (7).

The infection rate after elective nasal surgery is very low, making routine antibiotic prophylaxis redundant. Preventive systemic antibiotics are indicated in complicated revision rhinoplasties, prolonged placement of nasal packs and for patients who are susceptible to infections (7).

The administration of antibiotics is a common practice among otorhinolaryngologists for surgical procedures. The majority of the American Rhinology Society members use post-operative antibiotics routinely in septoplasties, which is considered unnecessary by many authors (5).

There are no significant differences among the groups (Group without antibiotics; Group - antibiotics only during the anesthetic induction; Group - antibiotics both in the anesthetic induction and post-operatively for seven days) concerning pain, fever, nausea, vomits, bleeding and purulent secretion. None of the patients had hematoma or septal abscess. The groups also did not differ in respect to the quantity of purulent secretion (5).

The nasal surgeries are clean from contamination and do not need antibiotic prophylaxis because of the low infection risk (5).

Some recommend the use of prophylactic antibiotics rather than empirical postoperative antibiotics for patients undergoing complex septorhinoplasty (2).

Although most of the authors do not agree with routine antibiotic prophylaxis after septo- and rhinoplasty, we perform it. In our practice, most of our patients leave the clinic after the 24th hour and the next examination is on the 6th/7th day. During the time when we are not with our patients, they can experience acute inflammation. Another reason to perform antibiotic prophylaxis is to use the intranasal splint for 6 / 7 days.

Our experience showed that small group of our patients without corticosteroid and antibiotic prophylaxis made a slower recovery.

## CONCLUSION

In this review, the variables of postoperative care after septo- and rhinoplasty are studied in terms of their value. An algorithmic approach to postoperative care, techniques and problems is discussed for evaluating the results from the abovementioned operative methods. Complications rate can be reduced by strictly following the exact postoperative care standards, a meticulous technique, recognition of pitfalls and early attention to perioperative morbidity. In conclusion, we can confirm that there is no "golden standard" for postoperative care as a whole. The postoperative care is more effective when we are aware of their strengths and weaknesses and we combine them individually for each patient.

## REFERENCES

1. Недев П. Септопластика. Изд. Геа-принт - Варна 2008. ISBN 978-954-9430-35-6. стр. 124.
2. Andrews PJ, East CA, Jayaraj SM, Badia L, Panagamuwa C, Harding L.; Prophylactic vs postoperative antibiotic use in complex septorhinoplasty surgery: a prospective, randomized, single-blind trial comparing efficacy. *Arch Facial Plast Surg.* 2006 Mar-Apr;8(2):84-7.
3. Ardehali MM, Bastaninejad S.; Use of nasal packs and intranasal septal splints following septoplasty. *Int J Oral Maxillofac Surg.* 2009 Oct;38(10):1022-4. Epub 2009 Jul 4.
4. Awan MS, Iqbal M.; Nasal packing after septoplasty: a randomized comparison of packing versus no packing in 88 patients. *Ear Nose Throat J.* 2008 Nov;87(11):624-7.
5. Caniello M, Passerotti GH, Goto EY, Voegels RL, Butugan O. Antibiotics in septoplasty: is it necessary? *Braz J Otorhinolaryngol.* 2005 Nov-Dec;71(6):734-8.
6. Dubin MR, Pletcher SD Postoperative packing after septoplasty: is it necessary? *Otolaryngol Clin North Am.* 2009 Apr;42(2):279-85, viii-ix.

7. Georgiou I, Farber N, Mendes D, Winkler E. The role of antibiotics in rhinoplasty and septoplasty: a literature review. *Rhinology*. 2008 Dec; **46**(4):267-70.
8. Gürlek A, Fariz A, Aydoğan H, Ersöz-Oztürk A, Evans GR., Effects of high dose corticosteroids in open rhinoplasty. *J Plast Reconstr Aesthet Surg*. 2009 May; **62**(5):650-5. Epub 2008 Mar 24.
9. G.J. Nolst Trenité, RHINOPLASTY, A practical guide to functional and aesthetic surgery of the nose, Kugler Publications, The Hague, The Netherlands, ISBN Book: 90 6299 206 4, 31-37 pages
10. Kargi E, Hoşnüter M, Babuççu O, Altunkaya H, Altinyazar C. Effect of steroids on edema, ecchymosis, and intraoperative bleeding in rhinoplasty. *Ann Plast Surg*. 2003 Dec; **51**(6):570-4.
11. Kula M, Yuce I, Unlu Y, Tutus A, Cagli S, Ketenci I. Effect of nasal packing and haemostatic septal suture on mucociliary activity after septoplasty: an assessment by rhinoscintigraphy *Eur Arch Otorhinolaryngol*. 2010 Apr; **267**(4):541-6. Epub 2009 Oct 13.
12. Lemmens W, Lemkens P. Septal suturing following nasal septoplasty, a valid alternative for nasal packing? *Acta Otorhinolaryngol Belg*. 2001; **55**(3):215-21.
13. Michael Evan Sachs, M.D. MASTERING REVISION RHINOPLASTY *Springer*, New York 2006, ISBN-10:0-387-98904-8, ISBN-13:978-0387-98904-4
14. Nedev P. Cranio-caudal transdomal sutures for the nasal tip correction. *European Archives of Oto-Rhino-Laryngology and Head & Neck*, Volume 266, Number 2 / February, 2009, pp 1434-4726
15. Ozdel O, Kara CO, Kara IG, Sevinc D, Oguzhanoglu NK, Topuz B. Does corticosteroid usage in rhinoplasty cause mood changes? *Adv Ther*. 2006 Sep-Oct; **23**(5):809-16.
16. Rhee SC, Kim JS. A simple method of fabricating nasal packing armed with ventilation tube. *J Craniofac Surg*. 2008 Sep; **19**(5):1385-6.
17. Salassa JR, Pearson BW. Polyethylene oxide gel. A new intranasal dressing after septorhinoplasty *Arch Otolaryngol Head Neck Surg*. 1991 Dec; **117**(12):1365-7.