COMPLETE SPINAL DYSRAPHISMS: RACHISCHISIS, CRANIORACHISCHISIS, INIENCEPHALY

Tanya Kitova[1], Kristina Kilova[2], Denis Milkov[2], Victor Marchev[2], Daniel Vassilev[2], Soumeya Siala Gaigi[3]

[1]Department of Anatomy, Histology and Embryology, Medical University of Plovdiv
[2]Medical University of Plovdiv
[3]Clinic of Fetopathology, Center of Maternity and Neonatology, Tunis

ABSTRACT

INTRODUCTION: World statistics show that neural tube defects (NTDs) rank foremost among congenital malformations. In 2002, the first gene of craniorachischisis was found – the Van-gl 2 gene. It was found by a cloning loop – tail (LT) gene for the defective closure of the neural tube. OBJECTIVE: To epidemiologically characterize the complete spinal dysraphisms: rachishisis, craniorachis-hisis and iniencephaly.

MATERIALS AND METHODS: Thirty-three fetuses with complete spinal dysraphisms were examined dur-ing the period 2006-2009 at the Center for Maternity and Neonatology – Tunisia. The fetuses were the re-sult of pregnancy terminations for medical reasons, intrauterine fetal death, and spontaneous abortions.

RESULTS: Ten (30.3%), eleven (33.3%) and twelve (36.4%) of the fetuses were respectively carriers of rachischi-sis, craniorachischisis and iniencephaly. Almost half of the fetuses were from first pregnancy mothers. The de-viation in the amount of amniotic fluid (oligoamnios) is an important endogenous risk factor. Exogenous risk factors are the time of conception (seasons) and endemic areas. Consanguinity is also a positive risk factor in 23% of fetuses with complete spinal dysraphisms. A mother's blood type A+ is the most common for the group (46.2%).

CONCLUSION: Preceding births of fetuses with complete spinal dysraphisms should motivate obstetricians to explore with caution each following pregnancy. The diagnosis of complete spinal dysraphisms is possible by biochemical tests, ultrasound (12, 22 weeks), MRI and genetic testing. Evidence of a malformation should be followed by the termination of the pregnancy.

Key words: *rachischisis, craniorachischisis, iniencephaly, risk factors, oligoamnios*

INTRODUCTION

Craniorachischisis has been a known, as a severe congenital malformation that can be combined with cyclopia and anencephaly, since the 18th century. The disease is found in the works of Hicks (1), Oakley and Grimshaw (2), Sedano and Gorlin (3), and Saint-Hilaire (4). World statistics show that neural tube defects (NTDs) rank foremost among congenital malformations. According to EUROCAT (European Surveillance of Congenital Anomalies), following an analysis of births in 22 European countries, neural tube defects were at a rate of 2.3 per 1000 births for the period 2003-2007 (5). The frequency of craniorachischisis ranges, but the highest incidence is found in China (6).

Experimental mouse embryos - mutants obtained by a selection of genes by the „knocking out" method are used as models for studies of

Address for correspondence:
Tanya Kitova
Department of Anatomy, Histology and Embryology
Bul. V. Aprilov 15A
Medical University of Plovdiv, Plovdiv 4003
Phone: 0887855857
e-mail: tanyakitova@yahoo.com

Received: January 30, 2013
Accepted: February 11, 2013

Copyright © Medical University of Varna

candidate genes responsible for the formation and closure of the neural tube (7), as well as phenotypes such as anencephaly, myelomeningocele and craniorachischisis. In 2002, the first gene of craniorachischisis was found - the Vangl 2 gene. It was found by a cloning loop - tail (LT) gene for the defective closure of the neural tube (8).

Planar cell polarity (PCP) signaling was investigated in drosophils and it was found that it participates in the gastrulation of the vertebrate embryos and the strabismus, while in homozygous mutants, causes craniorachischisis (9).

Several congenital abnormalities including neural tube, heart and lung defects and their relationship to the disruption of PCP signalization could be studied using the chuzhoi mutant (10).

OBJECTIVE

To epidemiologically characterize the complete spinal dysraphisms: rachishisis, craniorachischisis and iniencephaly.

MATERIALS AND METHODS

Thirty-three fetuses with complete spinal dysraphisms were examined during the period 2006-2009 at the Center for Maternity and Neonatology – Tunisia. The fetuses were the result of pregnancy terminations for medical reasons, intrauterine fetal death, and spontaneous abortions. The data for the mother and the fetus was collected in a file of autopsy findings from the fetus and the placenta. The information collected was about the age of the mother, the number of previous pregnancies and births, types of medications taken, the pathology of pregnancy, blood group data, consanguinity, place, method and the term of pregnancy. The birth weight, gender, gestation week and origin (single or multiple pregnancies) were recorded for each fetus. The file contains data from the karyotype study, fetal biometry, autopsy and diagnosis, as well as, photographic documentation.

RESULTS

- Ten (30.3%) of the studied fetuses were carriers of a congenital brain malformation affecting the spinal cord throughout its whole length. The arcs and processes of the vertebrae were missing. The vertebral canal contained a rudimentary spinal cord. The defect was not covered with skin. These cases were diagnosed as rachischisis.
- Eleven of the cases (33.3%) had complete bones from the roof of the skull missing, a lack of cerebral hemispheres, defects of the arcs and processes of the vertebrae along the spine, and no spinal cord. There is no skin in the area of the defect. These cases were a combination of anencephaly and rachischisis and were diagnosed as craniorachischisis (Figure 1).
- In twelve of fetuses (36.4%), the malformations appeared to be indicators of craniorachischisis but with a strongly expressed cervico-thoracic lordosis due to a defect of the occipital bone and the occipital foramen magnum. These cases were diagnosed as iniencephaly (Figure 2).
- The microscopic examination of the transition zone in the three defects showed a strongly modified tissue with ectasic blood vessels and congestion. The brain tissue of the cerebral hemispheres in rachischisis had a normal architecture in half of the cases (Figure 3).

Characteristics of the mothers:

- Average age – 30.53±1.09, with a range of 16 to 43 years. Complete spinal dysraphisms can be carried by mothers of any age (Figure 4). A mother's age of 25-30 is the most common (36%) for the fetuses with the malformations. An age of over 35 is the second most common (33%).
- Number of previous pregnancies - The study of the number of previous pregnancies is based on the 32 cases for which data was available. Nearly half of the fetuses are from primary pregnancies (47%), over a quarter of the studied (28%) are from mothers carriers of a second pregnancy. With three or more than three previous pregnancies are generally a quarter 25% of the mothers (Figure 5). Average number of births – more than 50% of the mothers carriers of fetuses with complete spinal dysraphisms had no previous births.
- Blood group – we have data on the blood groups of twenty-six mothers. Most numerous are the mothers with blood type A+, followed by those with B+ respectively, 46.2% and 26.9%. We have

Scripta Scientifica Medica, vol. 45, 2013, suppl. 1, pp. 75-80
Copyright © Medical University of Varna



Fig. 1. A male fetus weighing 344 grams with craniorachischisis. It was the result of an abortion during the 15th week of gestation. The mother was 27 years old and from Zaguan (Tunisia), a known endemic area. She had two previous pregnancies and her marriage was not consanguineous



Fig. 2. A female fetus with iniencephaly weighing 1500 grams. It is the result of a spontaneous abortion at 32nd week of gestation. The mother was 23 years old. She had one previous pregnancy and her marriage is consanguineous

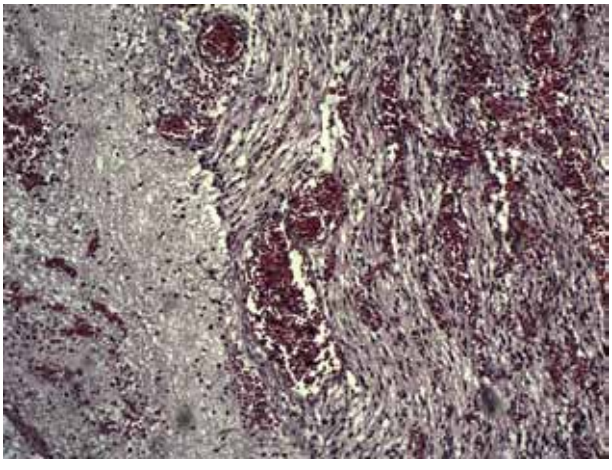

Fig. 3. Microscopic results. Disorganized cerebral masse with angiomatosis in case of rachischizis

no registered mothers with the blood group AB, who carried a child with craniorachischisis, rachischisis or iniencephaly (Table 1).

- Consanguinity – we have data on the type of marriage in 22 of the cases. In 77% of cases there was no consanguinity, for the remaining 23% there is evidence of consanguinity to a different degree (Figure 6).

In the obstetrics and gynecological diagnosis, it is noteworthy that 10% of the cases were from the regions of Gafsa and Zaguan (known as endemic areas). In 5% of the cases there was evidence of eclampsia and oligoamnios.

– 72.7% of the pregnancies were interrupted due to medical reasons, and 6.1% constitute miscarriages.

Copyright © Medical University of Varna

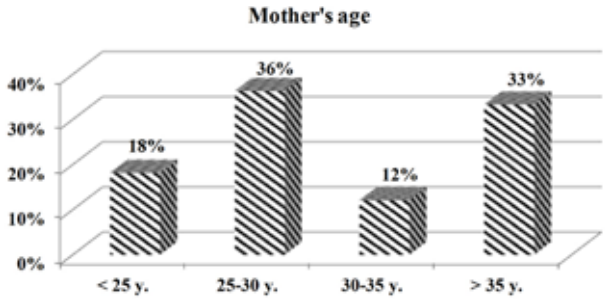

Fig. 4. Distribution by age of the mothers carriers of fetuses with complete spinal dysraphisms.

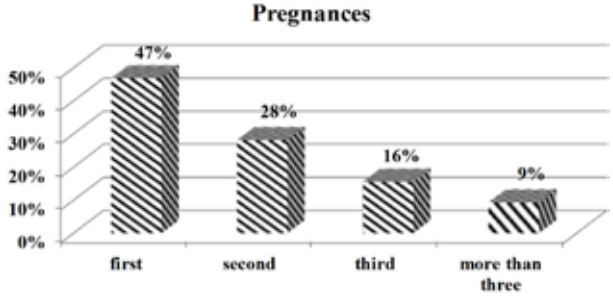

Fig. 5. Distribution of the number of pregnancies with complete spinal dysraphisms

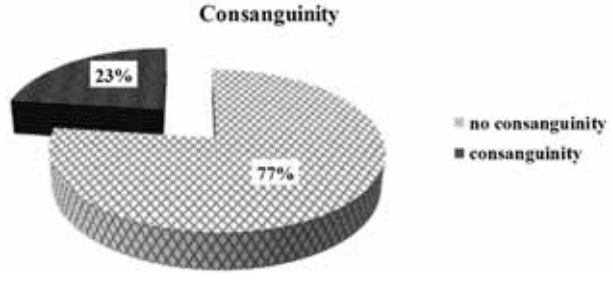

Fig. 6. Distribution by consanguinity



Fig. 7. Distribution by age of the fetus

Prenatal diagnosis:

In 21% of the cases the sonographic diagnosis was of anencephaly, followed by spina bifida (18%), exencephaly (12%) and a malformation in general (9%). At 3% each are dead fetuses, holoprosencephaly, trisomy 21 and hermaphroditism.

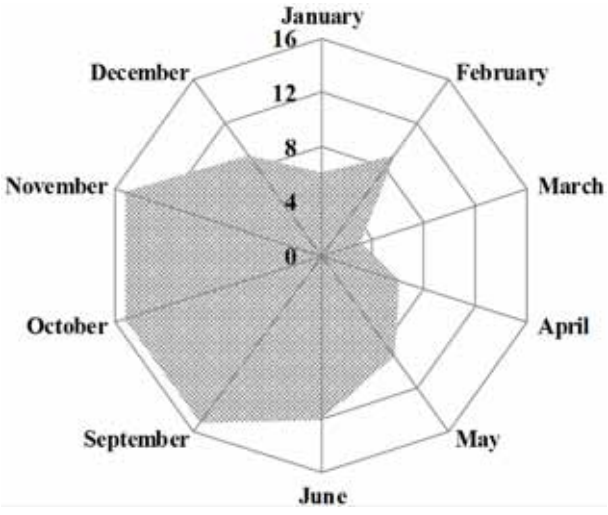

Fig. 8. Seasonal variations

Characteristics of fetuses:

- Anomalies affect both genders, but are more prevalent in females - 66.7% (Table 2). From the same table, it is apparent that the average weight is higher in male fetuses (594.64±203.72), compared to that of female (418.64±99.46), but this difference was not confirmed statistically ($u = 0.88$, $p > 0.05$).
- The average duration of the gestation (term) was 22.76±1.3 weeks. The shortest and longest terms were nine and thirty-four weeks, respectively ($n = 31$). In two cases there was no accurate data on the age of the fetus. In 80.65% of the cases, the

Tabl. 1. Distribution by the maternal blood group

Blood groups	Number of cases	Percent	Mean error
0+	4	15,38%	7,08%
0–	**2**	**7,69%**	**5,23%**
B+	7	26,92%	8,70%
A+	12	46,15%	9,78%
A–	**1**	**3,85%**	**3,77%**
Total	**26**	**100,00%**	-

Scripta Scientifica Medica, vol. 45, 2013, suppl. 1, pp. 75-80
Copyright © Medical University of Varna

Tabl. 2. Distribution by gender the of fetus

Sex of fetuses	Number of cases	Percent	Mean weight (g)	Mean error
Female	21	66,7%	418,64	±99,46
Male	11	33,35	594,64	±203,72
Total	32	100,0%		

expulsion of the fetuses is until the 28th week of gestation (Figure 7).

- A lower then normal fetal weight was found in 69.70% of the examined fetuses according to the reference values of Guilhard-Costa (11).
- A karyotype study was performed on seven cases of craniorachischisis, rachischisis and iniencephaly, representing 21.2% of all cases. One of the fetuses had a confirmed karyotype of trisomy 13, one of trisomy 21, and one case had chromosomal aberration.

Seasonal variations (Figure 8). The three studied abnormalities are more common when the conception period is autumn (September, October and November). There is also a small peak in February.

DISCUSSION

The complete spinal dysraphisms - rachischisis, craniorachischisis and iniencephaly - are incompatible with life as they are „great malformations" of the central nervous system. Iniencephaly is the most common malformation – 36.3%, followed by craniorachischisis – 33.3% and rachischisis – 30.3%. The average age of the mothers was 30 years, the youngest mothers represented 18% and nearly half of them were carriers of the first pregnancy. Malformations can occur in the first pregnancy of young mothers. More often, however, a mother's age of over 35 is a risk factor for complete spinal dysraphisms which supports the study of Golalipour (12). In this study, a seasonal variation was observed. The rate of NTDs was higher in the time period September to November. Seasonal variations in the prevalence of neural tube defect rates have been noted in other regions of the world. In a study in Ireland the rate was higher in the January to June period as compared to the July to December period. Also, in Ireland, there was a peak in April (13).

A deviation in the amount of the amniotic fluid – oligoamnios or polyhydramnios and premature rupture of the membrane is an important predictor for possible congenital abnormalities. Polyhydramnios is frequently associated with anencephaly (the mechanism is unclear) (14) and according to our study a deviation in the amount of amniotic fluid can be associated with complete spinal dysraphisms.

The malformations affected both genders but females were more frequently affected (67.0%) which supports the research of Afshar (15) The average weight of the fetuses in our study is 465.23 grams (SE±93.074) S 534.67, and in 69.70% of the fetuses with NTDs a deficiency in weight and hypotrophy was found. Similar data was found by Masmoudi (16). Fourine (17) associated reduced fetal weights with a prolonged duration of cell divisions, leading to the appearance of a number of weaker cells.

Consanguinity was present in 23% in the studied fetuses. According to the National Statistic Register of Tunisa, consanguinity marriages are at a rate of about 27%. This study found evidence of a less than average consanguinity. Complete spinal dysraphisms in 42.9% of the investigated cases with a karyotype are associated with trisomy 21, trisomy 13, and chromosomal aberrations. This study confirms the multifactorial genesis of the malformations and proves once again the importance of genetic counseling, karyotype studies and Fish hybridization in prenatal diagnosis.

CONCLUSION

A previous birth to a fetus with a complete spinal dysraphism should motivate obstetricians to explore with caution each following pregnancy. The complete spinal dysraphisms must be systematically sought in the course of pregnancy during prenatal diagnostic examinations. Their diagnosis is possible by biochemical tests, ultrasound (12, 22 weeks), MRI and genetic testing. The evidence of a malformation should be followed by the termination of the pregnancy.

Copyright © Medical University of Varna

REFERENCES

1. Hicks, S. P. Anencephaly, spina bifida cystica, encephalocele, diastematomyelia and Arnold Chiari malformation, holotelencephaly (arhinencephaly).- *Scientific Approaches to Clinical Neurology*, Vol. I, 1997, 604-615.
2. Oakley, N. W., J. S. Grimshaw. A case of iniencephaly associated with cyclopia.- *Br. J. Clin. Pract.*, **15**, 1961, 604-615, 27-36, 845-849.
3. Sedano, H., R. J. Gorlin. The oral manifestations of cyclopia: Review of the literature and report of two cases.- *Oral Surg. Oral Med. Oral Pathol.*, **6**, 1963, 823-838.
4. Saint-Hilaire, E. G. Contribution of one naturalist to medical knowledge.- *Hist. Sci. Med.*, **38**, 2004, No 3, 365-383.
5. Dolk, H., M. Loane, E. Garne. The prevalence of congenital anomalies in Europe.- *Adv. Exp. Med. Biol.*, **686**, 2010, 349-364.
6. Johnson, K. M., L. Suarez, M. Felkner, K. Hendricks. Prevalence of craniorachischisis in a Texas-Mexico border population.- *Birth Defects Res. A Clin. Mol. Teratol.*, **70**, 2004, No 2, 92-94.
7. Volcik, K. A., S. H. Blanton, M. C. Kruzel, I. T. Townsend, G. H. Tyerman, R. J. Mier et al. Testing for genetic associations in a spina bifida population: analysis of the HOX gene family and human candidate gene regions implicated by mouse models of neural tube defects.- *Am. J. Med. Genet.*, **110**, 2002, No 3, 203-207.
8. Murdoch, J. N., K. Doudney, C. Paternotte, A. J. Copp, P. Stanier. Severe neural tube defects in the loop-tail mouse result from mutation of Lpp1, a novel gene involved in floor plate specification.- *Hum. Mol. Genet.*, **10**, 2001, No 22, 2593-2601.
9. Kibar, Z., K. J. Vogan, N. Groulx, M. J. Justice, D. A. Underhill. Gros P Ltap, a mammalian homolog of Drosophila Strabismus/Van Gogh, is altered in the mouse neural tube mutant Loop-tail.- *Nat. Genet.*, **28**, 2001, No 3, 251-255.
10. Paudyal, A., C. Damrau, V. L. Patterson, A. Ermakov, C. Formstone, Z. Lalanne et al. The novel mouse mutant, chuzhoi, has disruption of Ptk7 protein and exhibits defects in neural tube heart and lung development and abnormal planar cell polarity in the ear.- BMC Dev. Biol., 10, 2010, 87.
11. Guilhard-Costa, A. M., J. C Larroche. Fetal biometry: charts for practical use in fetopathology and antenatal ultrasonoraphy.- *Fetal Diagn. Ther.*, **10**, 1995, 211-278.
12. Golalipour, M. J., L. Najafi, A. Keshtkar. Neural Tube Defects in Native Fars Ethnicity in Northern Iran. - *Iranian Journal Of Public Health.*, **3**, 2010, 116-123.
13. Mc Donnel, R. J., et al. East Ireland 1980-1994 epidemiology of neural tube defects.- *Epidemiology and community health*, **53**, 1999, No 12, 782-788.
14. Abd El Ghani, A., K. El Ansarry. Neural Tube Defects.- *Asjog.*, **3**, 2006. Available at http://www.asjog.org Accessed November 12, 2010
15. Afshar, M., M. Golalipour, D. Farhud. Epidemiologic aspects of neural tube defects in South East Iran.- *Neurosciences*, **11**, 2006, No 4, 289-292.
16. Masmoudi, A. Analyse de 900 examens foetopathologiques: Expérience du Centre de Maternité et de Néonatologie de la Rabta de Tunis. Thèse de Médcine, 1996.
17. Fournie, A., F. Lesourd-Pontonnier, T. Laffite. Physiologie de la croissance fœtale.- Encycl. Med. Chir. gynécolodie/obstétique, 1997, 5-019-A-05,5

Scripta Scientifica Medica, vol. 45, 2013, suppl. 1, pp. 75-80
Copyright © Medical University of Varna